Sodium Fluoride (F-18 NaF) Bone PET Imaging

Joanna R. Fair, M.D., Ph.D.
Associate Professor and Vice-Chair, Radiology
Section Chief, Nuclear Medicine
University of New Mexico Hospital/Albuquerque VAMC

Acknowledgements and Disclosures

- Some images courtesy of Michael Hartshorne, M.D.
- Nothing to disclose

Questions

- Similarities and differences of NaF and MDP?
- What do NaF PET scans look like?
- How are they done?
  - Patient preparation
  - Technical details
  - Scheduling logistics
  - Radiation exposure
- Accuracy?
- How/why can they be ordered?

NaF / MDP similarities / differences? What do NaF PET scans look like?

F smaller than MDP

F-18 NaF

- Salt
- Dissolves: Na^+ / F^- ions
- Smaller



Tc-99m MDP

- Bisphosphonate analog
- Chelator
- Larger

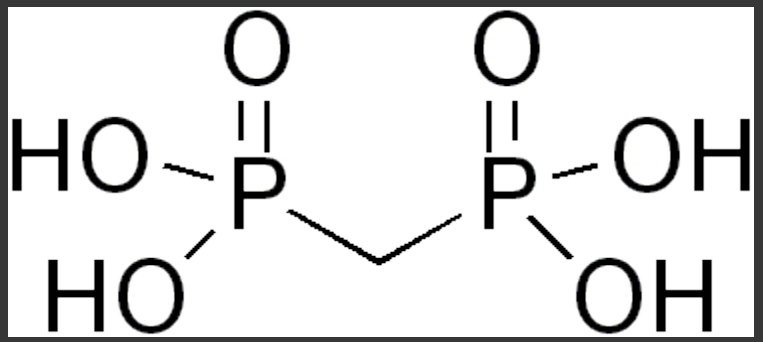

NaF imaged sooner

F-18 NaF

- Bone agent
  - Localizes to high blood flow and high osteoblastic activity
- Uptake via passive diffusion
  - Smaller à FASTER
  - 2x higher uptake
- Renal clearance
  - FASTER ~ 1 hr
  - Less background

Tc-99m MDP

- Bone agent
  - Localizes to high blood flow and high osteoblastic activity
- Uptake via passive diffusion
  - Larger à SLOWER
- Renal clearance
  - SLOWER ~ 3 hrs
  - More background

Li Y, et al, Bone 50 (2012): 128–139

PET better efficiency/resolution

	PET scanners	Gamma cameras
Detection efficiency	~1%	~0.01%
Spatial resolution	3-6 mm	4-15 mm

Li Y, et al, Bone 50 (2012): 128–139

F-18 NaF vs Tc-99m MDP

NaF
Rectilinear Scanner

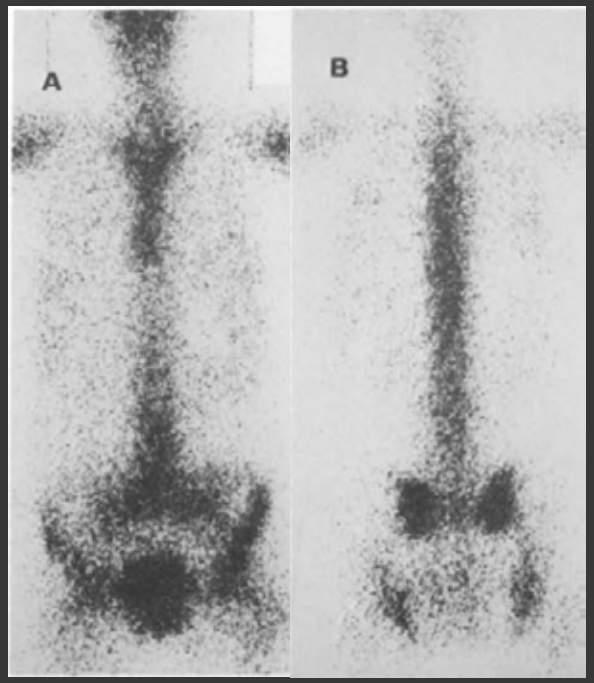

MDP
Gamma Camera

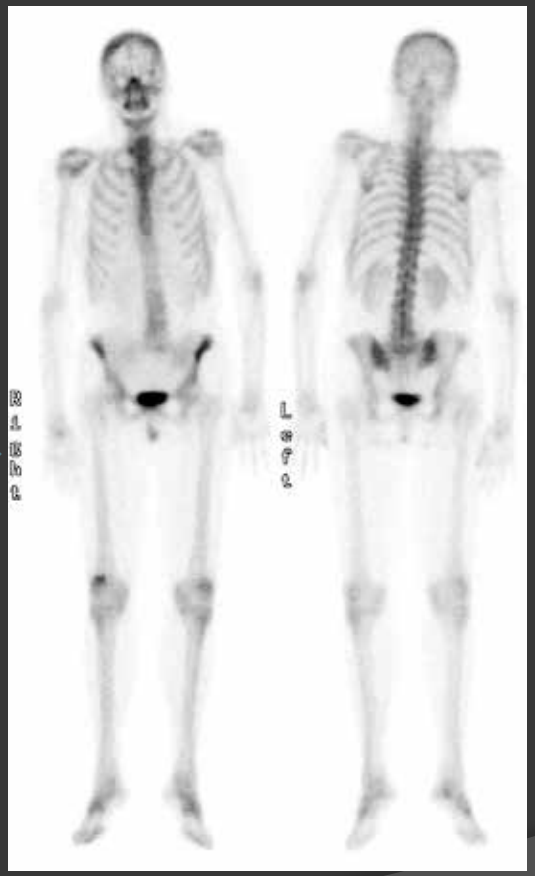

NaF
PET Scanner

Silberstein EB et al.
Radiology 107 (1973): 551-555

Li Y et al.
Bone 50 (2012): 128–139

NaF MDP

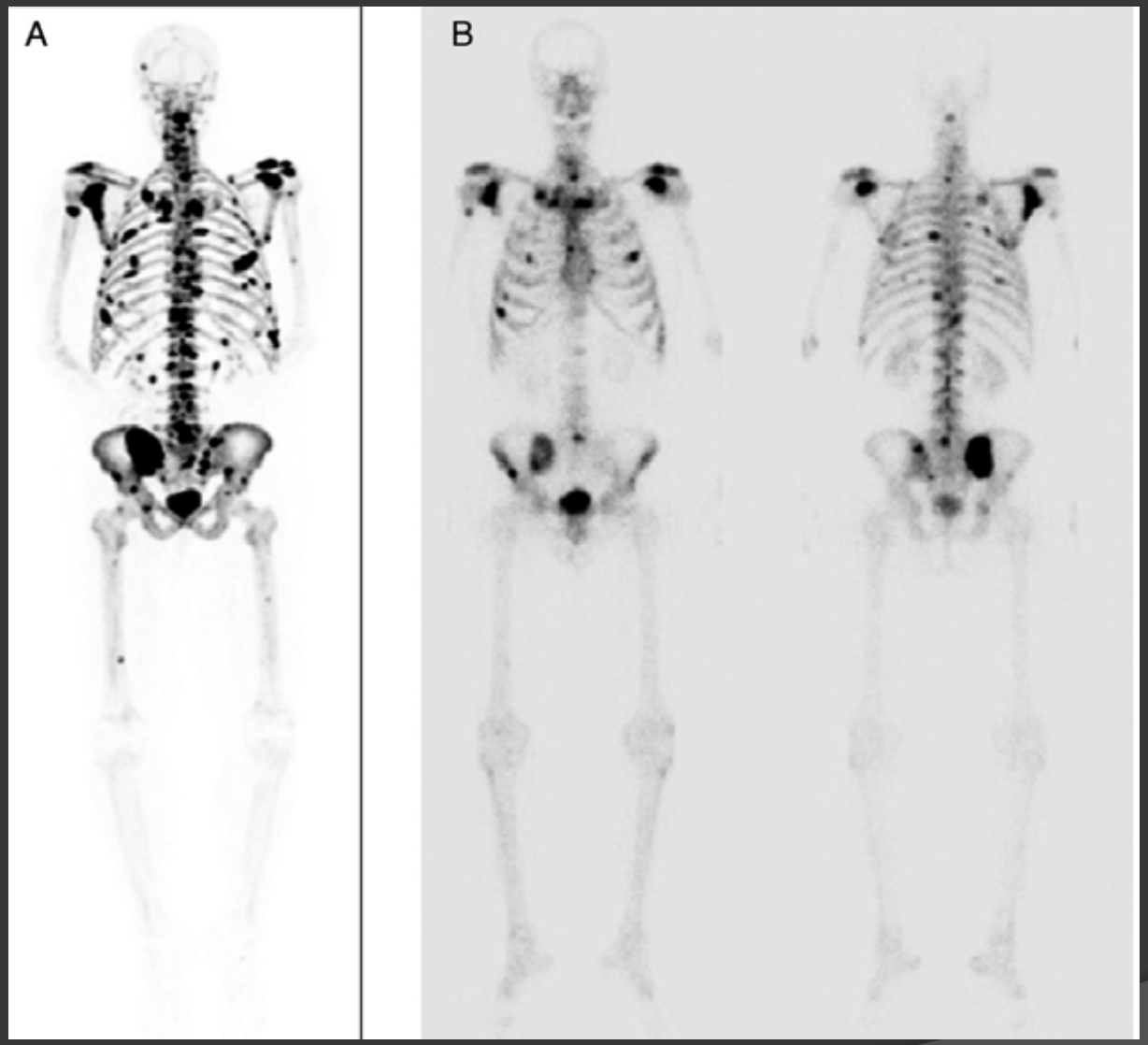

Both go to bone

Both renally excreted

Both greater uptake in axial than appendicular skeleton

Greater lesion conspicuity with NaF

Li Y, et al, Bone 50 (2012): 128–139

NaF: Tomo & CT more available

F-18 NaF

- Tomographic imaging routine

PET-CT widely available – automatic anatomic correlation

Tc-99m MDP

- Planar imaging routine

SPECT or SPECT-CT not routine

NaF PET: Normal

Superscans (same patient)

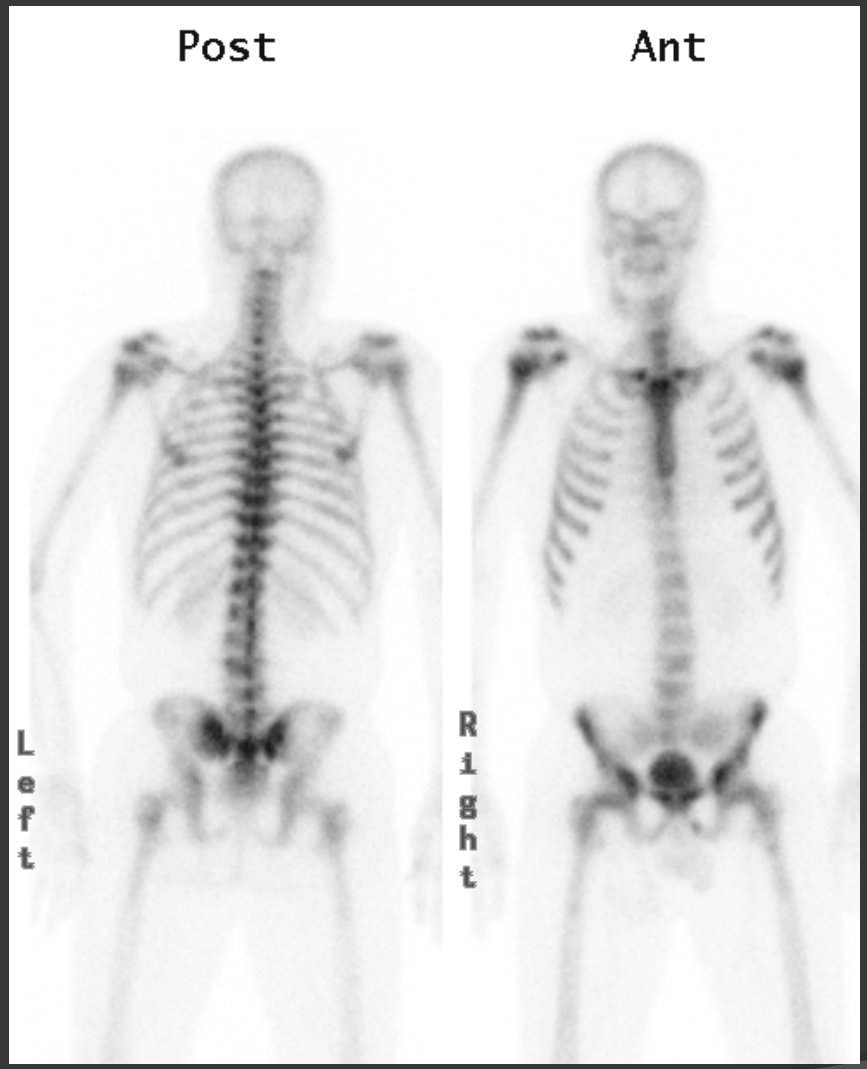

MDP

NaF

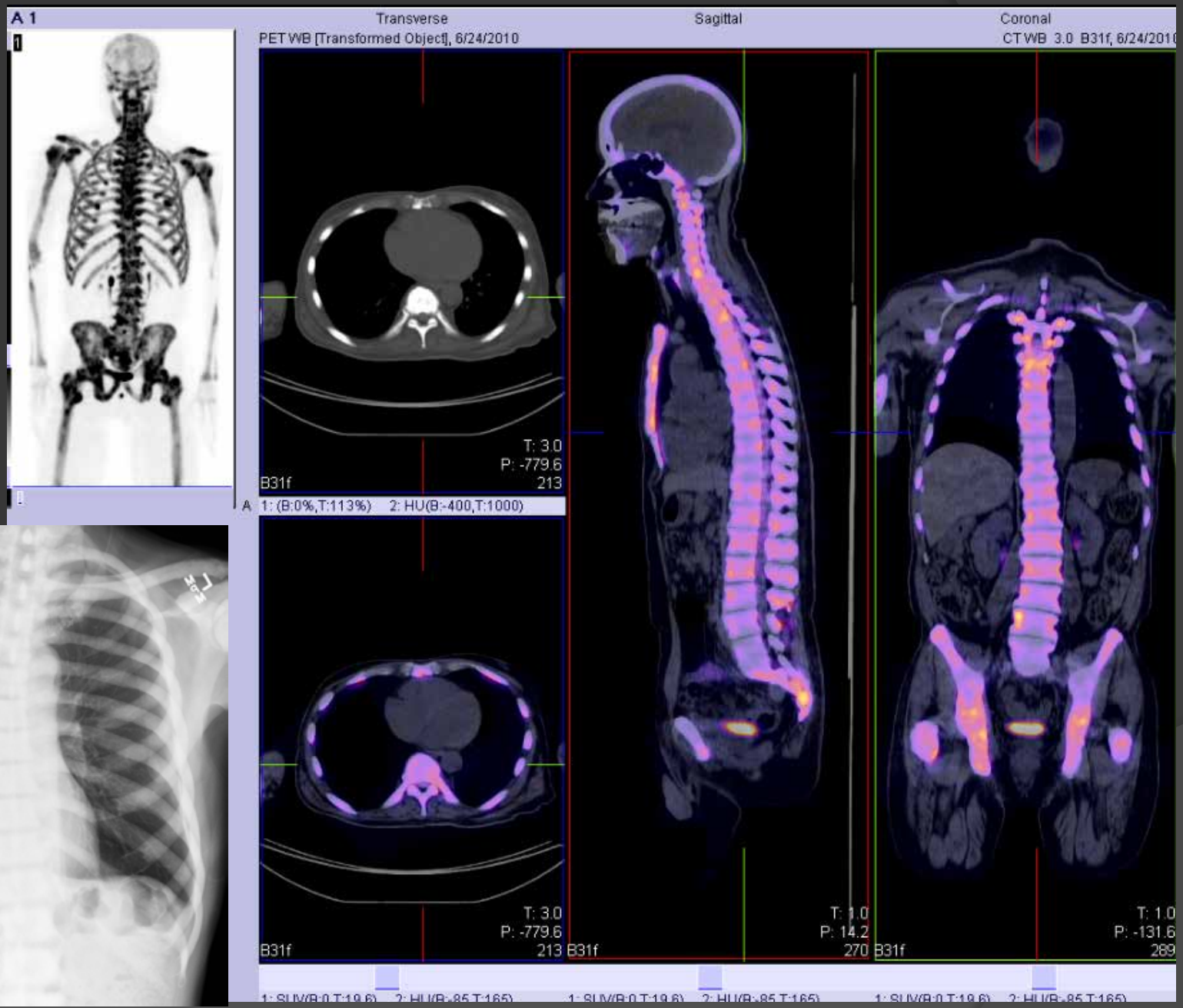
A 1
Transverse
Sagittal
Coronal
PET WB [Transformed Object], 6/24/2010
CT WB 3.0 B31f, 6/24/2010
T: 3.0
P: -779.6
B31f
213
A 1: (B:0%,T:113%) 2: HU(B:-400,T:1000)
T: 3.0
P: -779.6
B31f
213
T: 1.0
P: 14.2
B31f
270
T: 1.0
P: -131.6
B31f
289

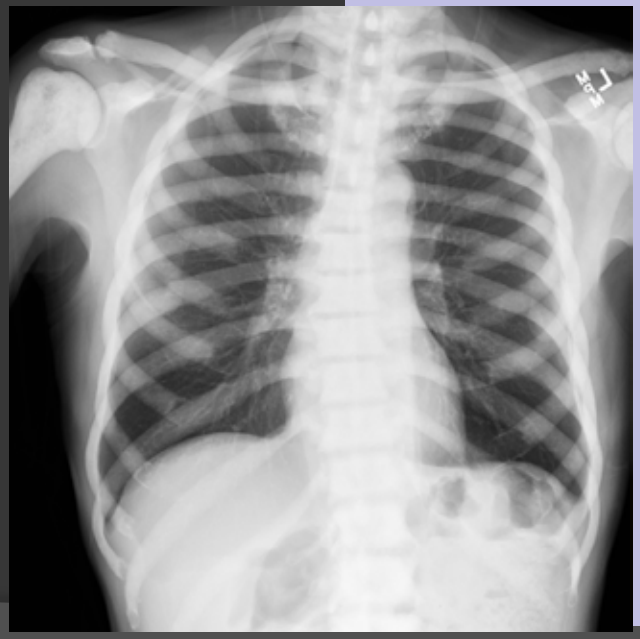

Take-home points

- NaF and MDP localize similarly
  - Osteoblastic activity (bone turnover)
- NaF better image quality
  - Faster bone uptake
  - Faster renal clearance
  - Better detection efficiency and spatial resolution
- Both have tomographic images
  - NaF PET-CT routine
  - MDP extra imaging time

How are NaF PET bone scans performed?

How are NaF PET bone scans performed?

- Patient preparation
- Imaging protocol
- Scheduling logistics
- Radiation exposure

SNM Practice Guideline for Sodium ^{18}F-Fluoride PET/CT Bone Scans 1.0*

George Segall[1], Dominique Delbeke[2], Michael G. Stabin[2], Einat Even-Sapir[3], Joanna Fair[4], Rebecca Sajdak[5], and Gary T. Smith[6]

[1]VA Palo Alto Health Care System, Palo Alto, California; [2]Vanderbilt University Medical Center, Nashville, Tennessee; [3]Tel Aviv Sourasky Medical Center, Tel Aviv, Israel; [4]Mallinckrodt Institute of Radiology, St. Louis, Missouri; [5]Loyola University Medical Center, Chicago, Illinois; and [6]Tennessee Valley Veterans Administration Medical Center, Nashville, Tennessee

THE JOURNAL OF NUCLEAR MEDICINE • Vol. 51 • No. 11 • November 2010

www.snmmi.org

Patient prep like MDP

- Like MDP bone scan
  - Well hydrated (fluids before and after)
- Unlike FDG PET
  - No fasting needed
  - Blood glucose not a problem

Whole-body imaging protocol

- 5-10 mCi F-18 NaF, IV
- Scan at 30-45 min (longer OK)
- Parameters
  - Skull to thighs or toes
  - Arms down
- 20-40 min scan
  - Similar to whole-body planar MDP
- Low-dose CT

SNM Practice Guideline for Sodium 18F-Fluoride PET/CT Bone Scans 1.0, 2010

Scheduling can coordinate with FDG PET

- Bone PET day
  - Limits availability
- Intersperse with FDG
  - Use 1 hr post-injection delay
  - Caveat: Can’t substitute an early or late patient for an FDG slot

NaF PET/CT higher radiation exposure

F-18 NaF

- F-18 NaF dose
  - 5 mCi * 0.89 mSv/mCi =
  - 4.5 mSv (450 mrem)
  - Target organ = bladder
- Low-dose CT
  - 3.2 mSv (320 mrem)
- Total 7.7 mSv (770 mrem)

Tc-99m MDP

- Tc-99m MDP dose
  - 30 mCi * 0.21 mSv/mCi =
  - 6.3 mSv (630 mrem)
  - Target organ = bone surfaces

Best case: NaF PET-CT ~125% of Tc-99m MDP

Li Y, et al, Bone 50 (2012): 128–139

CT gives AC and anatomy

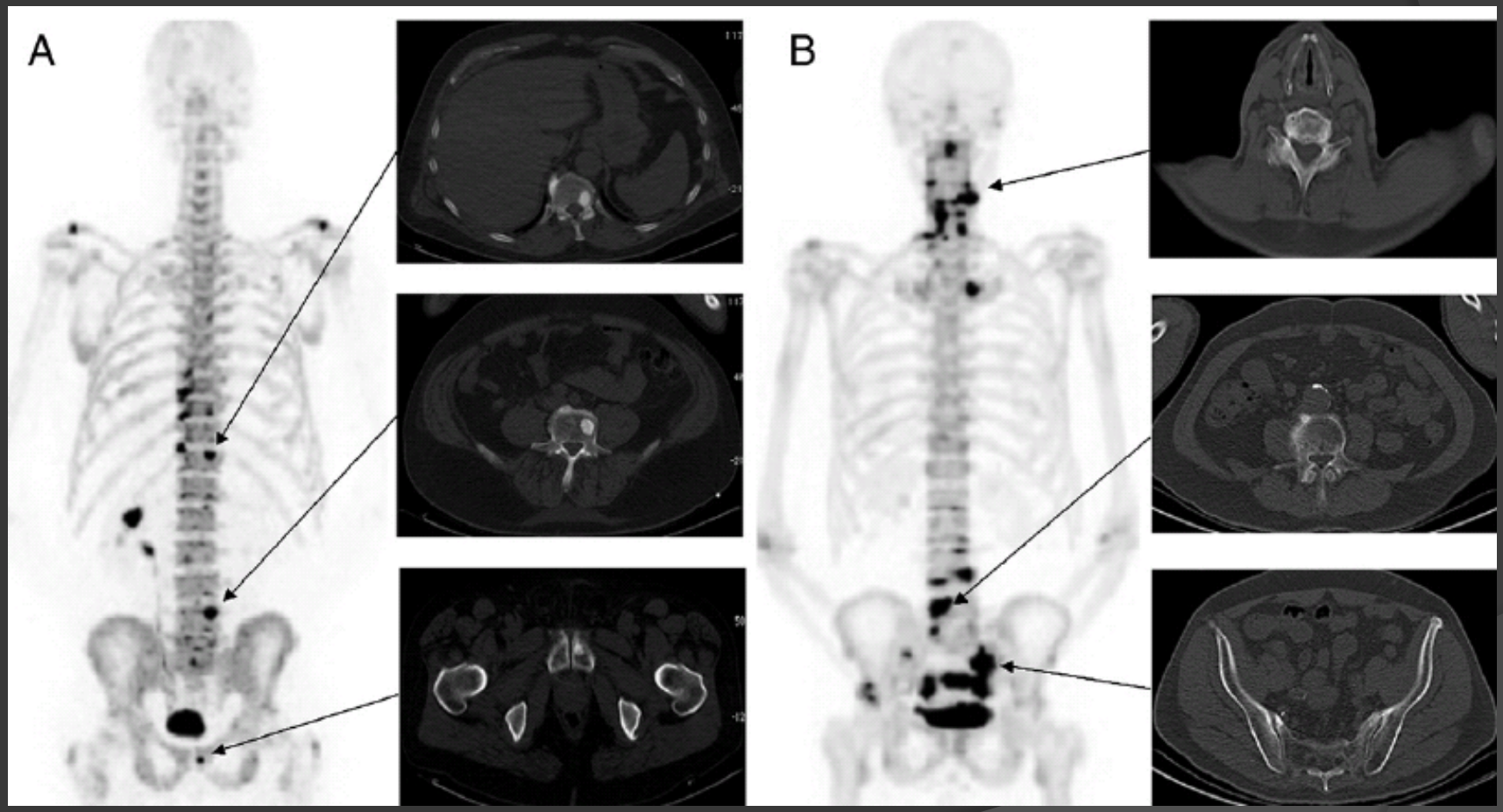

Mets and degenerative changes Degenerative changes only

Li Y, et al, Bone 50 (2012): 128–139

CT improves accuracy

- Even-Sapir 2004: NaF PET vs. NaF PET-CT
  - 44 patients, variety of cancers
  - 212 lesions (111 malignant, 89 benign, 12 indeterminate)
  - Patient-based results

	Sensitivity	Specificity
NaF PET	88%	56%
NaF PET-CT	100%	88%
	($P<0.05$)	(not significant)

Even-Sapir E, et al, J Nucl Med 45 (2004): 272-278

Take-home points

- Patient prep
  - Hydration (NaF same as MDP)
- Injection-to-imaging time
  - NaF (~30-60 min) shorter than MDP (~3 hours)
- Scheduling
  - Between FDGs or separate day
- Radiation exposure
  - NaF PET-CT higher than MDP (~25%) *with lowest NaF activity and low-dose CT*
  - CT improves accuracy

What are the indications for NaF PET? How accurate are they?

Indications

Primary Indication

- Identify skeletal metastases
  - Localization
  - Extent of disease

In Progress

- Back pain, unexplained bone pain
- Child abuse
- Abnormal x-ray or lab findings
- Osteomyelitis
- Trauma
- Inflammatory/degenerative arthritis
- Avascular necrosis
- Osteonecrosis of the mandible
- Condylar hyperplasia
- Metabolic bone disease
- Paget disease
- Bone graft viability
- Complications of prosthetic joints
- Reflex sympathetic dystrophy
- Distribution of osteoblastic activity before therapeutic radiopharmaceuticals for bone pain

SNM Practice Guideline for Sodium 18F-Fluoride PET/CT Bone Scans 1.0, 2010

NaF better than MDP in:

- Prostate CA (Even-Sapir E, J Nucl Med 47 (2006): 287-297)
- Lung CA (Schirrmeister H et al, J Nucl Med 42 (2001): 1800-1804)
- Breast CA (Schirrmeister H et al, J Clin Oncol 17 (1999): 2381-2389)
- Hepatocellular CA (Yen RF Nucl Med Commun 31 (2010):637-645)

NaF better than planar or SPECT MDP

- Tateishi et al.
  - Metaanalysis
  - 11 studies, 350 patients

Table 2 Independent estimates of analyses on patient basis and lesion basis

Diagnostic methods	No. of studies	Sensitivity (95% CI)	Specificity (95% CI)
Analysis on a patient basis			
BS planar	5	0.468 (0.398–0.537)	0.883 (0.829–0.936)
BS planar and SPECT	3	0.815 (0.706–0.923)	0.990 (0.973–1.000)
^{18}F-Fluoride PET	7	0.949 (0.912–0.986)	0.987 (0.972–1.000)
^{18}F-Fluoride PET/CT	3	0.977 (0.938–1.000)	0.959 (0.905–1.000)
BS planar or BS planar and SPECT	8	0.569 (0.510–0.627)	0.980 (0.964–0.996)
^{18}F-Fluoride PET or PET/CT	10	0.962 (0.935–0.989)	0.985 (0.970–1.000)
Analysis on a lesion basis			

Tateishi U et al, Ann Nucl Med 24 (2010): 523-531

Why order an NaF bone scan? How can it be paid for?

Two reasons

- Negative MDP but ongoing suspicion
  - 4/12 patients with (-) MDP scan had (+) NaF PET-CT

- Contribute to knowledge about how NaF bone scans change patient management and outcomes
  - National Oncologic PET Registry (NOPR) for NaF Bone Scans

Even-Sapir E, et al, J Nucl Med 45 (2004): 272-278

NOPR NaF assessed management changes

- Referring physician asked before and after the NaF PET:

"If you were to continue your patient's management without doing any other testing first, what would be your treatment plan?"

  - Continue current therapy
  - Modify dose or schedule
  - Switch therapy
  - Stop therapy

Hillner BE, J Nucl Med. 2015 Feb;56(2):222-8

NaF PET changed **management** in 40% . . .

- Comparable to role of FDG PET for treatment monitoring

. . . but coverage denied

- CMS 12/15/2015:
  - NaF PET is NOT reasonable and necessary
  - Continue CED for 24 months
- Future is unclear

Hillner BE, J Nucl Med. 2015 Feb;56(2):222-8; www.cms.gov

CASES

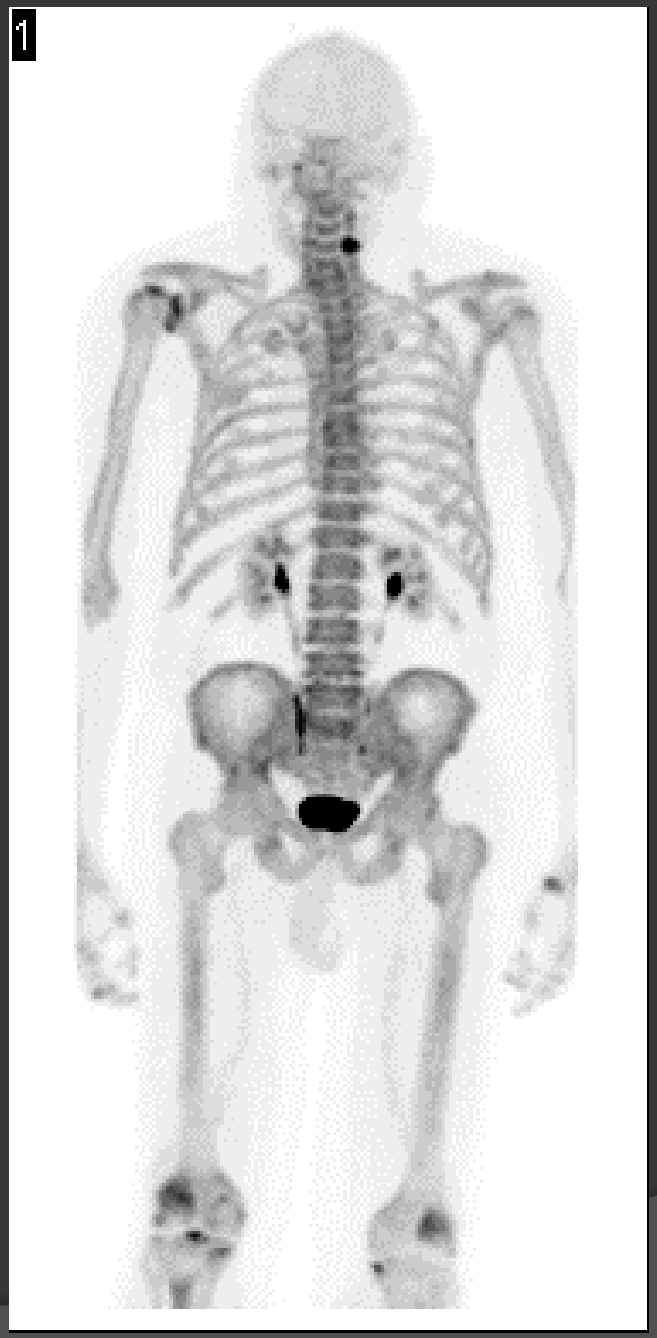
1

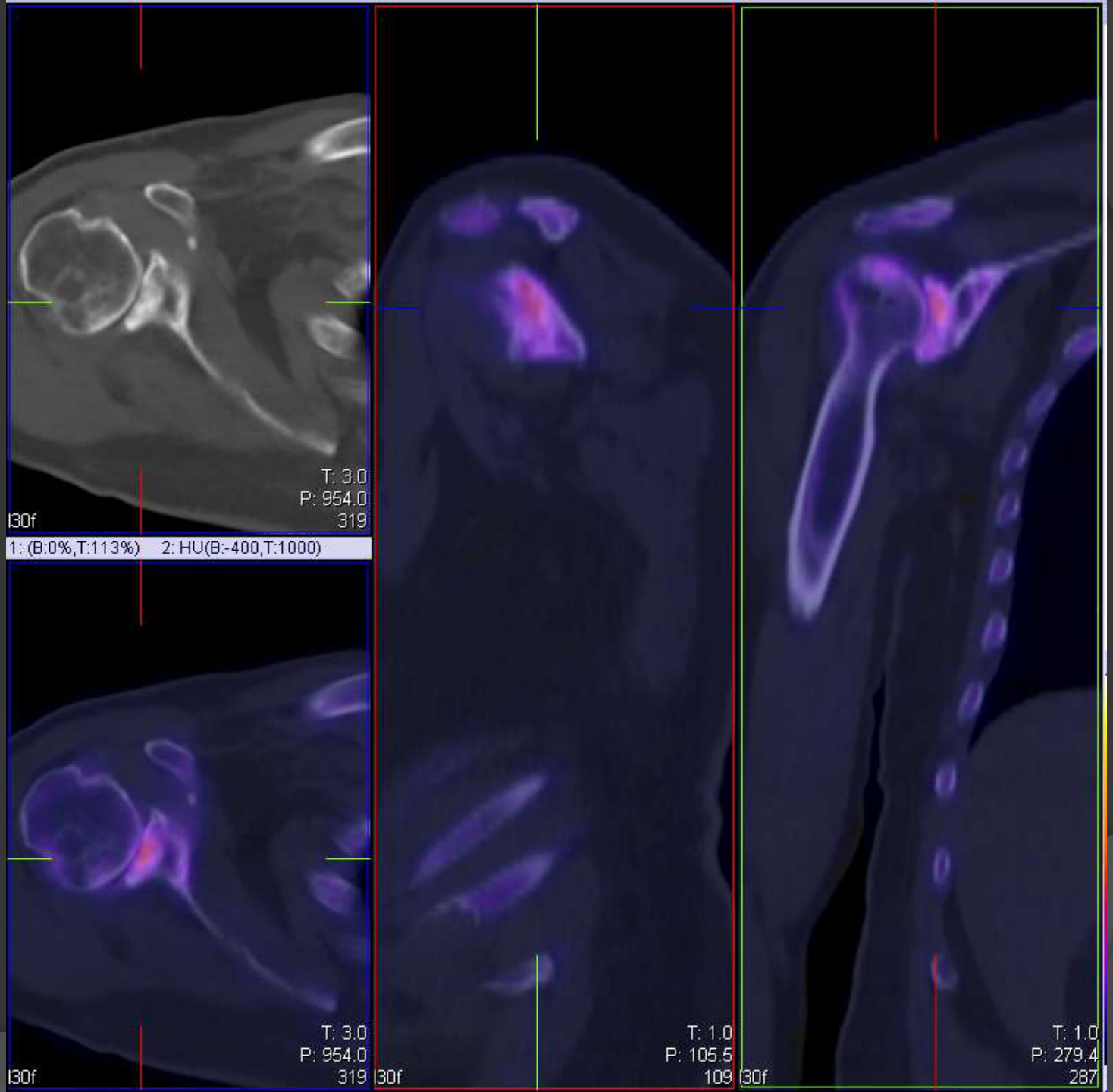
T: 3.0
P: 954.0
I30f
319
1: (B:0%,T:113%)
2: HU(B:-400,T:1000)
T: 3.0
P: 954.0
I30f
319
T: 1.0
P: 105.5
I30f
109
T: 1.0
P: 279.4
I30f
287

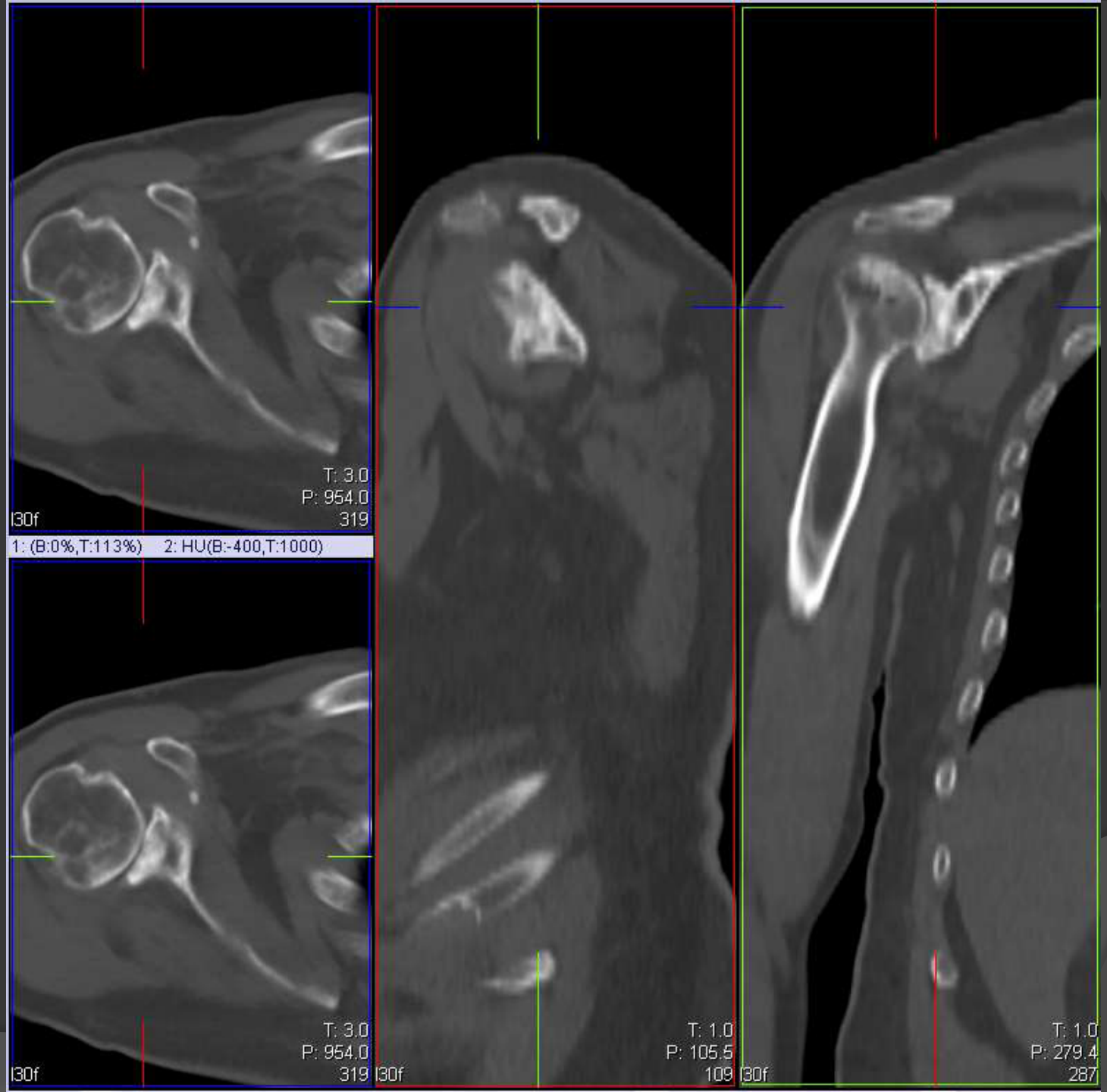
T: 3.0
P: 954.0
I30f
319
1: (B:0%,T:113%)
2: HU(B:-400,T:1000)
T: 3.0
P: 954.0
I30f
319
T: 1.0
P: 105.5
I30f
109
T: 1.0
P: 279.4
I30f
287

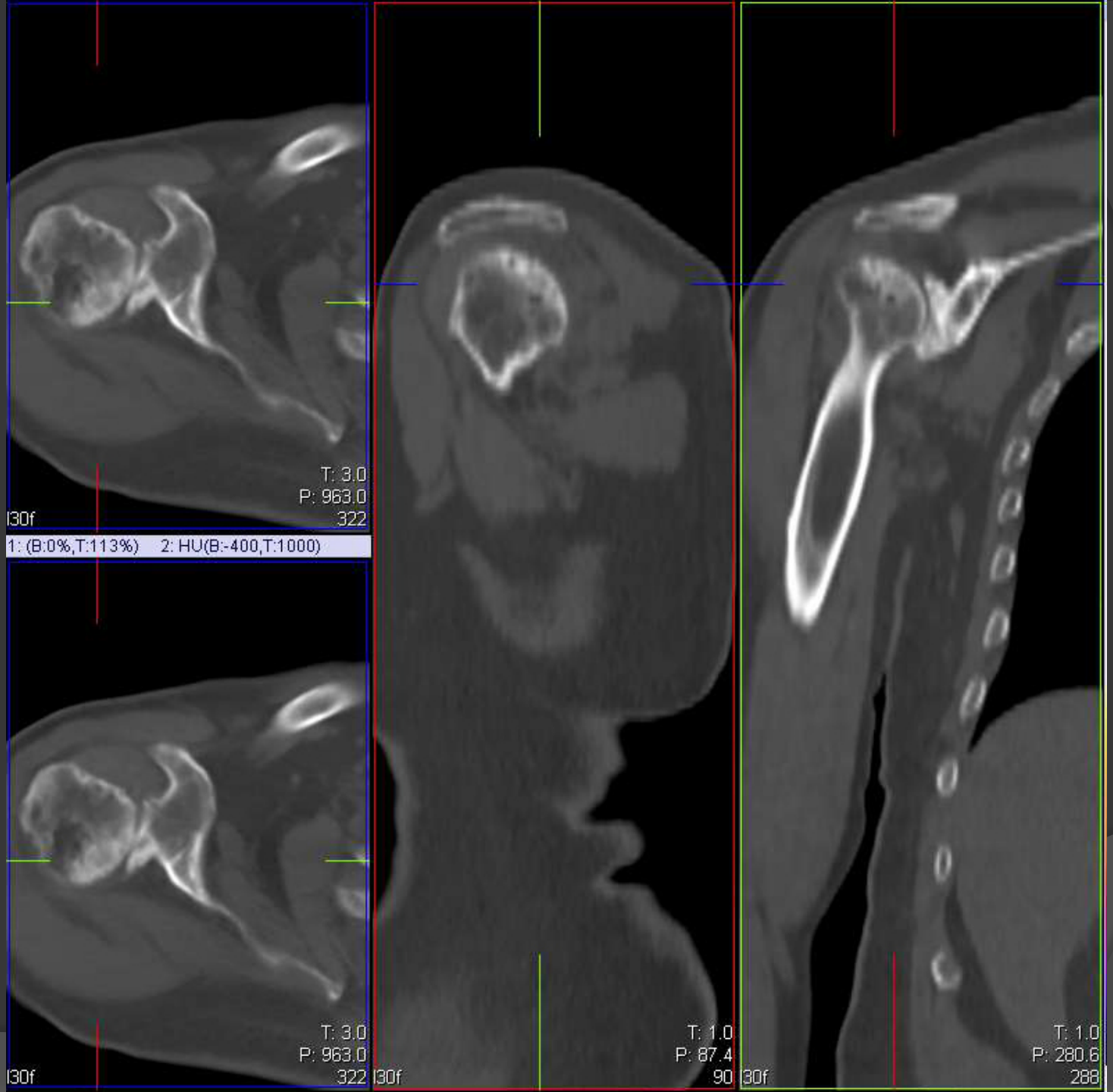
T: 3.0
P: 963.0
I30f
322
1: (B:0%,T:113%)
2: HU(B:-400,T:1000)
T: 3.0
P: 963.0
I30f
322
T: 1.0
P: 87.4
I30f
90
T: 1.0
P: 280.6
I30f
288


1

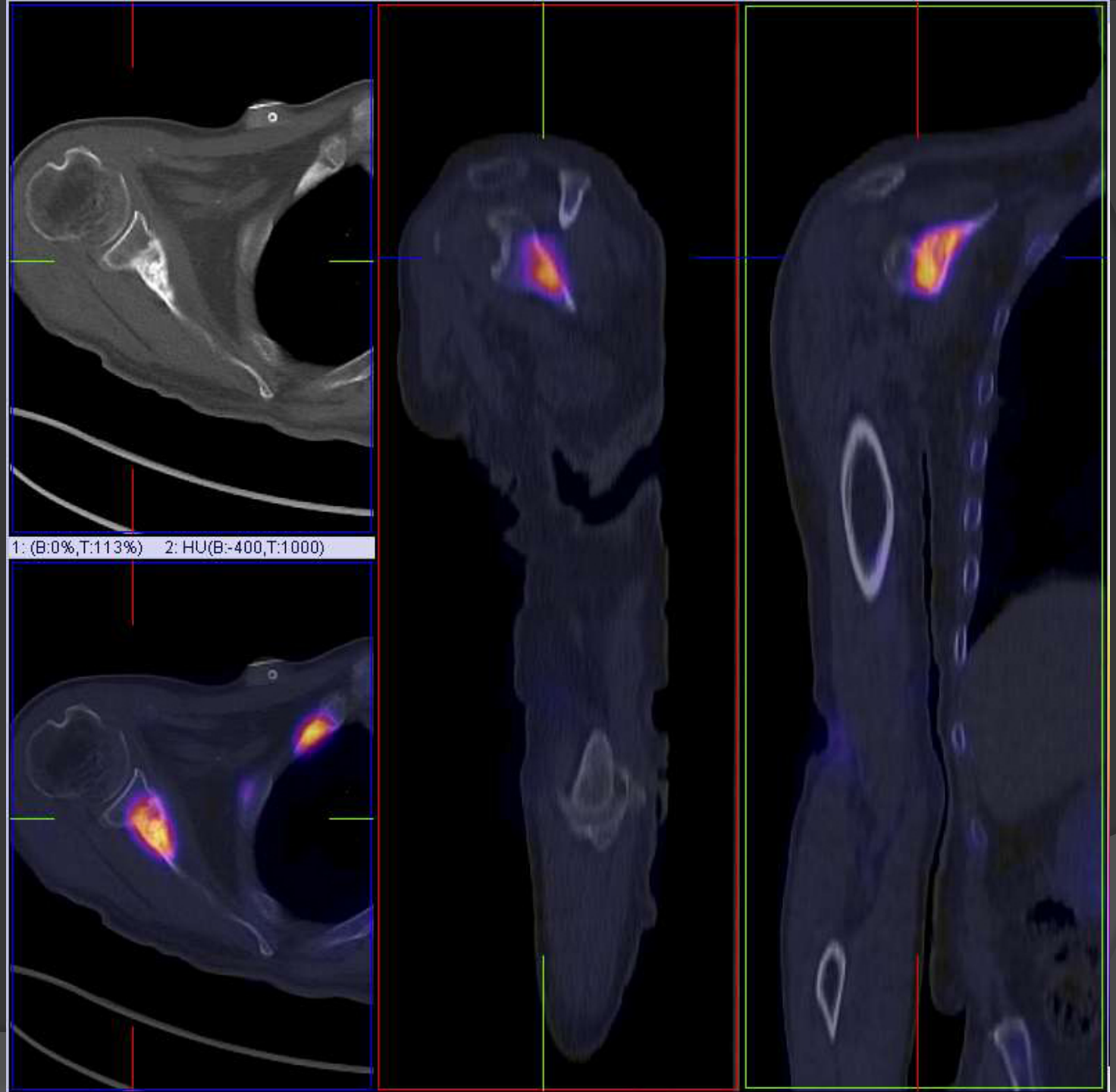
1: (B:0%,T:113%)
2: HU(B:-400,T:1000)

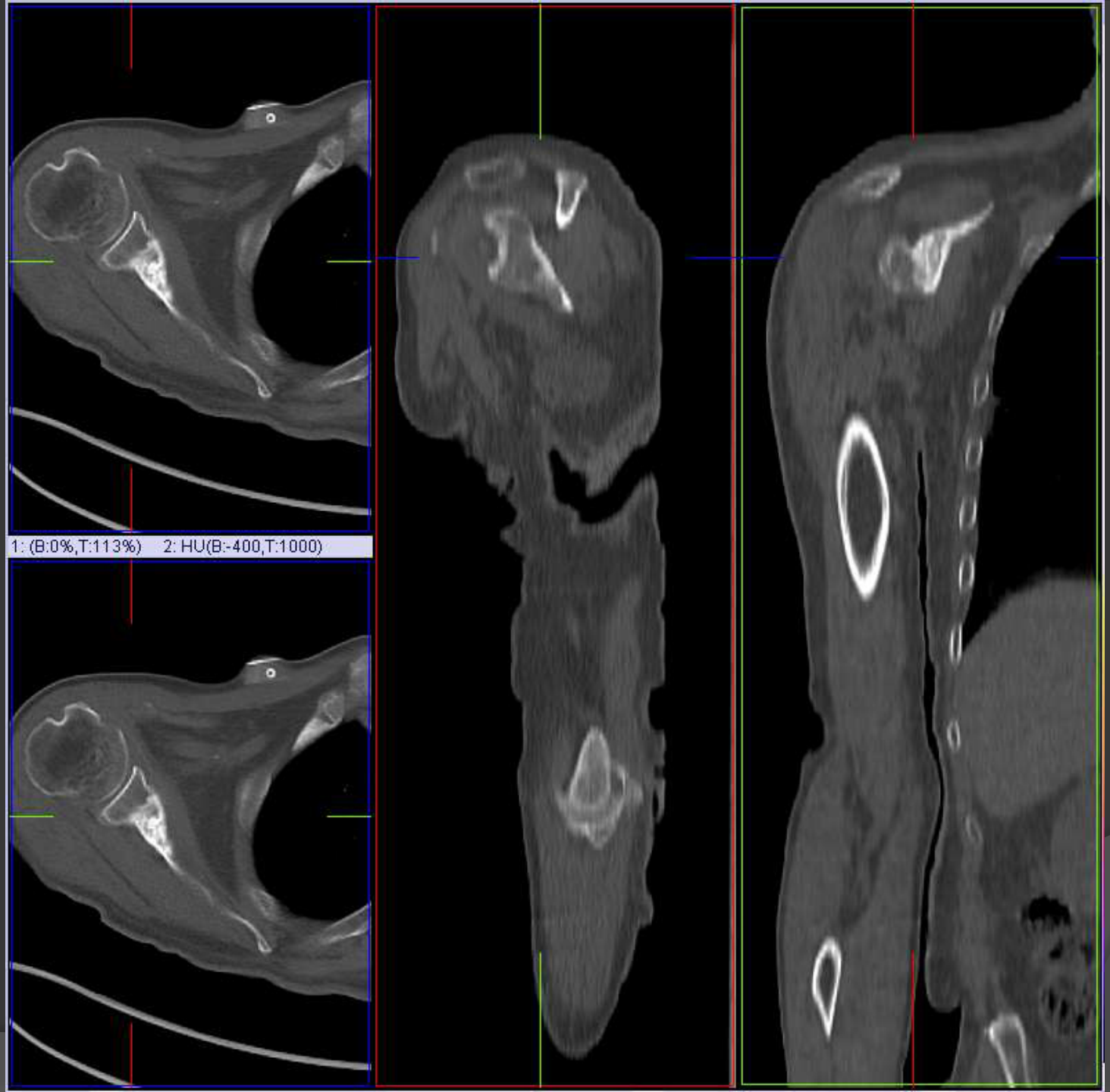
1: (B:0%,T:113%)
2: HU(B:-400,T:1000)

SAMs

SAM Question #1

- One <u>disadvantage</u> of F-18 NaF PET-CT compared with Tc-99m MDP is that NaF bone scans have:
  A. Less sensitivity for osseous metastases
  B. Less availability of direct anatomic correlation
  C. Longer image interpretation time
  D. Longer time from injection to imaging

SAM Question #1

- One <u>disadvantage</u> of F-18 NaF PET-CT compared with Tc-99m MDP is that NaF bone scans have:
  A. Less sensitivity for osseous metastases
  B. Less availability of direct anatomic correlation
  C. Longer image interpretation time
  D. Longer time from injection to imaging

SAM Question #2

- Mild, diffuse osseous uptake of F-18 NaF, with urinary excretion visualized, is most likely due to
  - Diffuse osseous metastases
  - Normal pattern
  - Recent marrow stimulating agents
  - Metabolic bone disorder

SAM Question #2

- Mild, diffuse osseous uptake of F-18 NaF, with urinary excretion visualized, is most likely due to
  - Diffuse osseous metastases
  - Normal pattern
  - Recent marrow stimulating agents
  - Metabolic bone disorder

SAM Question #3

- For F-18 NaF, the organ typically receiving the maximum radiation exposure is:
  - Bladder
  - Kidney
  - Bone marrow
  - Stomach

SAM Question #3

- For F-18 NaF, the organ typically receiving the maximum radiation exposure is:
  - Bladder
  - Kidney
  - Bone marrow
  - Stomach

Target organ for MDP is bone