Molecular Imaging in Movement Disorders

SNMMI SW Chapter Meeting

Arlington, TX

March 23rd, 2019

Ashlee Patterson, CNMT, NMTCB(CT)

UTSouthwestern
Medical Center

Disclosures

None

Objectives

- To review anatomy & physiology of the brain
- To review the following Movement disorders, and various imaging techniques of such disorders:
  - Parkinson's Disease/ Essential Tremors
  - Epilepsy
  - Primary Dystonia & Gilles de la Tourette Syndrome

- To review possible future applications of PET in:
  - Huntington's Disease
  - Amyotrophic Lateral Sclerosis

Basal Ganglia

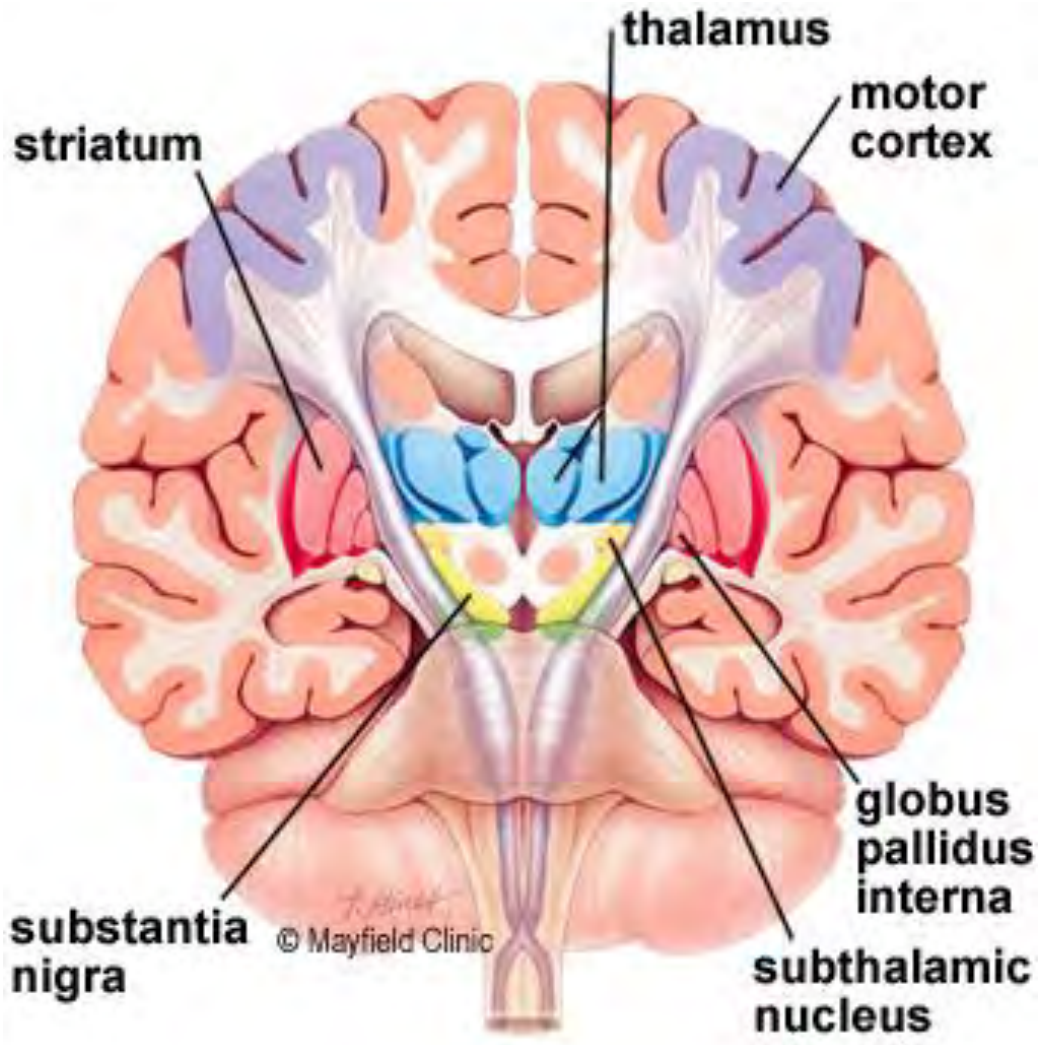

+ Glutamate

-GABA

Direct Motor Pathway

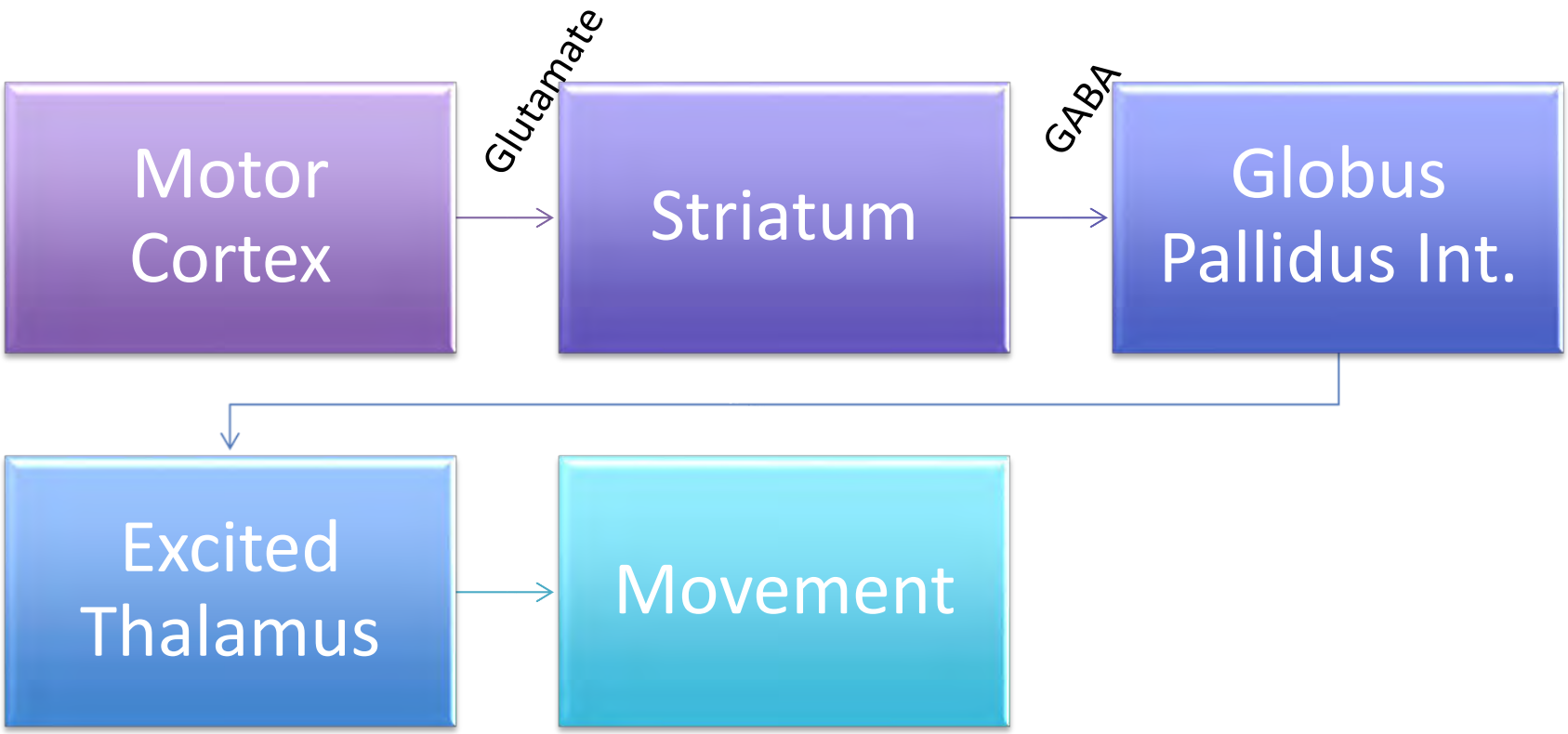

What Are Movement Disorders

"Movement disorders are a collection of neurologic syndromes characterized by deficits in the execution of voluntary movement, but in the absence of significant muscle weakness or paralysis, loss of sensation or proprioception, or of spinal cord or peripheral nerve lesions."

3,9

Why Use MI for Diagnosing Movement Disorders?

Direct visualization of Brain Function

Identifying disease in its earliest stages

Treatments & Surgical Planning

1, 9

Essential Tremor & Parkinson's Disease

Essential Tremor & Parkinson's Disease

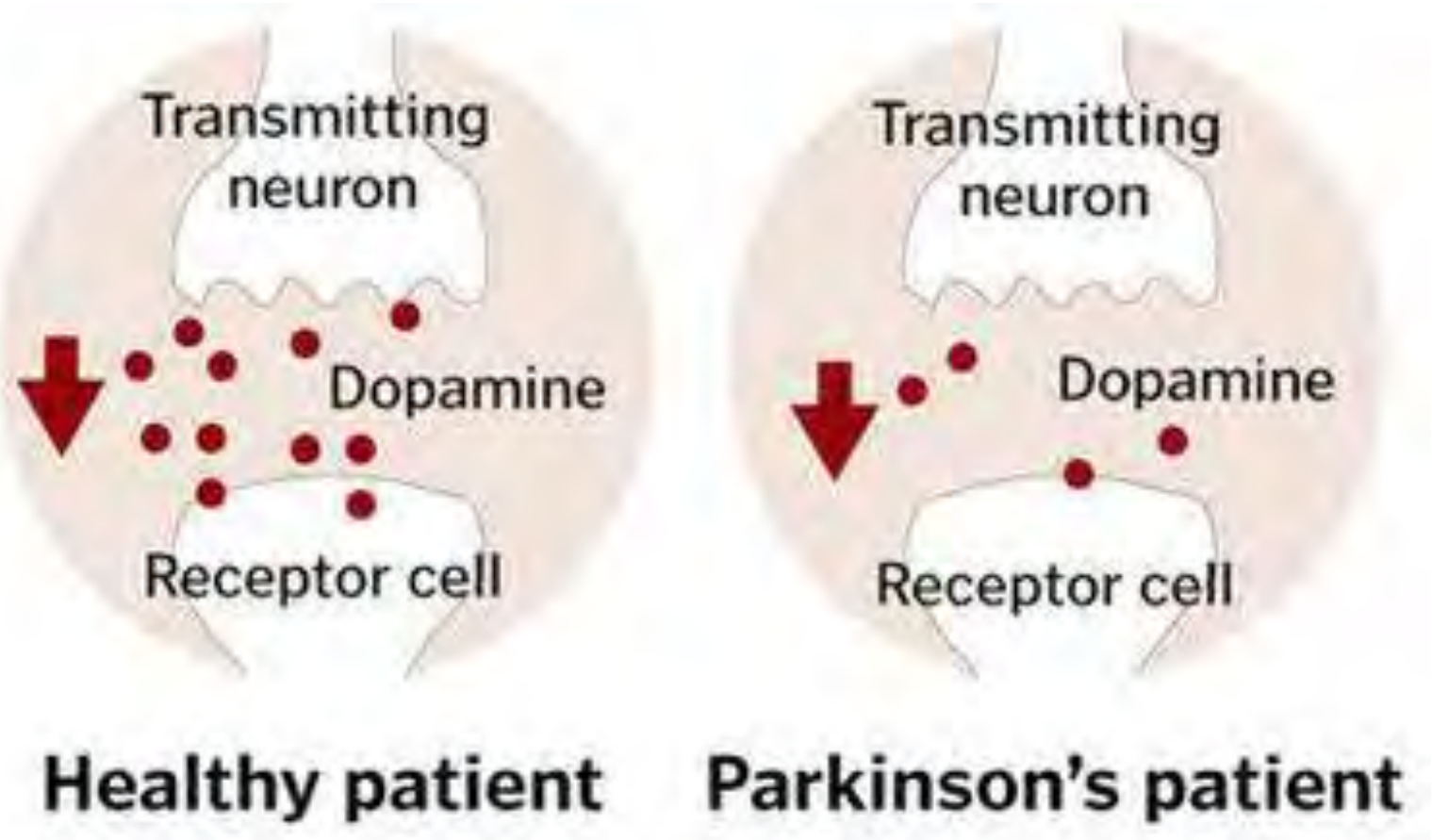

ET Vs PD Methods of Imaging

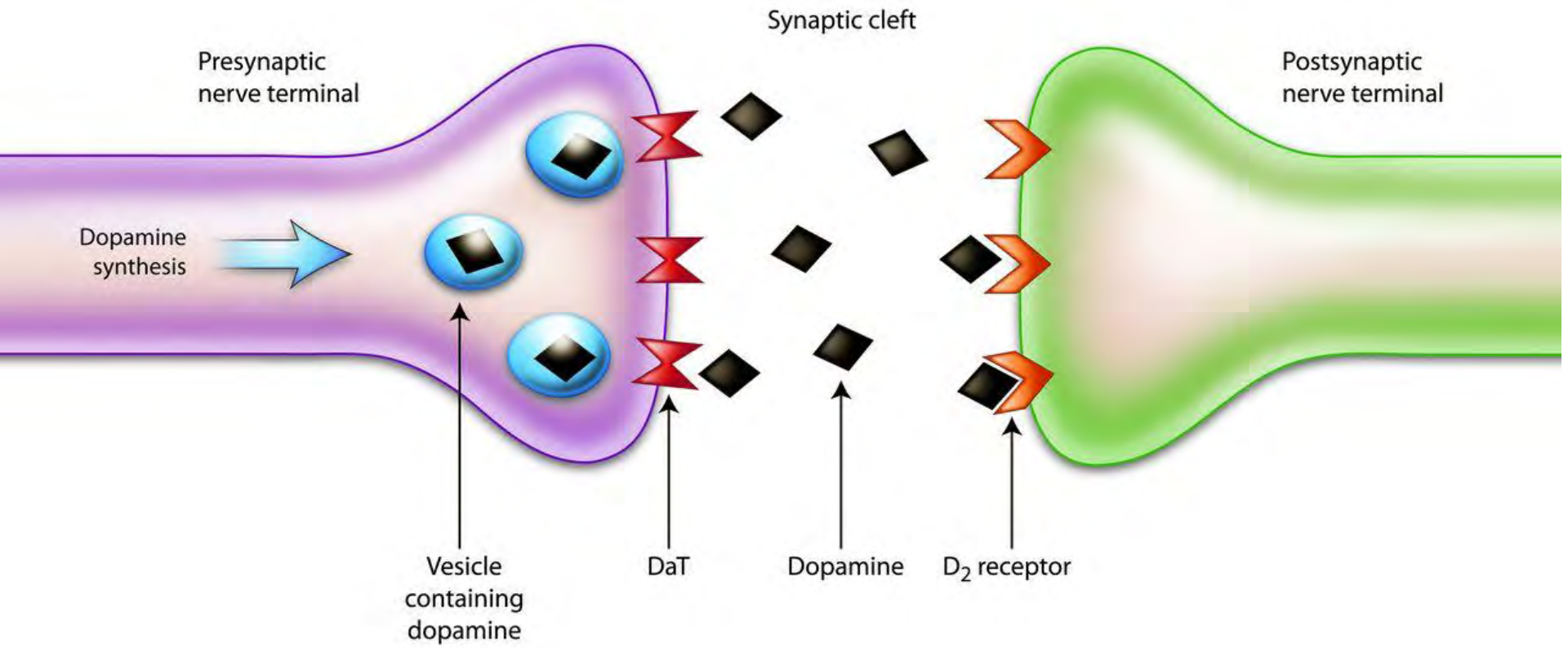

DaT Scan Protocol

I-123 Ioflupane (DaT Scan)
Dose: 5 mCi
Delay time: 3-5 hrs

Prep

- Thyroid blocking agent 1 hr pre-injection
  - Equivalent to 100mg Iodine

Injection

- 5 mCi I-123 Ioflupane (DaT Scan) IV

Imaging

- 3-5 hour post injection
- 30-35 min SPECT using LEHR or Fan Beam

Normalization Structure: DaTscan Atlas: Occipital Lobe

Atlas	Structure	Z-Sc...	L Z-Score	R Z-Score	L-R % Diff	L-R % Diff Z-Score
DaTscan Atlas	Caudate	1.05	1.27	0.77	6.54	0.9
DaTscan Atlas	Anterior Putamen	1.09	1.12	1.02	1.5	0.34
DaTscan Atlas	Striatum	1.23	1.33	1.13	3.75	0.73
DaTscan Atlas	Putamen	1.33	1.34	1.3	0.52	0.35
DaTscan Atlas	Posterior Putamen	1.5	1.44	1.51	0.91	0.09
DaTscan Atlas	Occipital Lobe	Norm	Norm	Norm	Norm	Norm

Structure	Z-S...	L Z-Score	R Z-Score	L-R % Diff	L-R % Diff Z-Score
Anterior Putamen/Posterior Putamen	-1.06	-0.64	-1.1	0.58	0.24
Caudate/Putamen	-0.98	-0.48	-1.08	6.02	0.44

Normal DaT Scan Values

DaT Scan for Dementia Vs PD

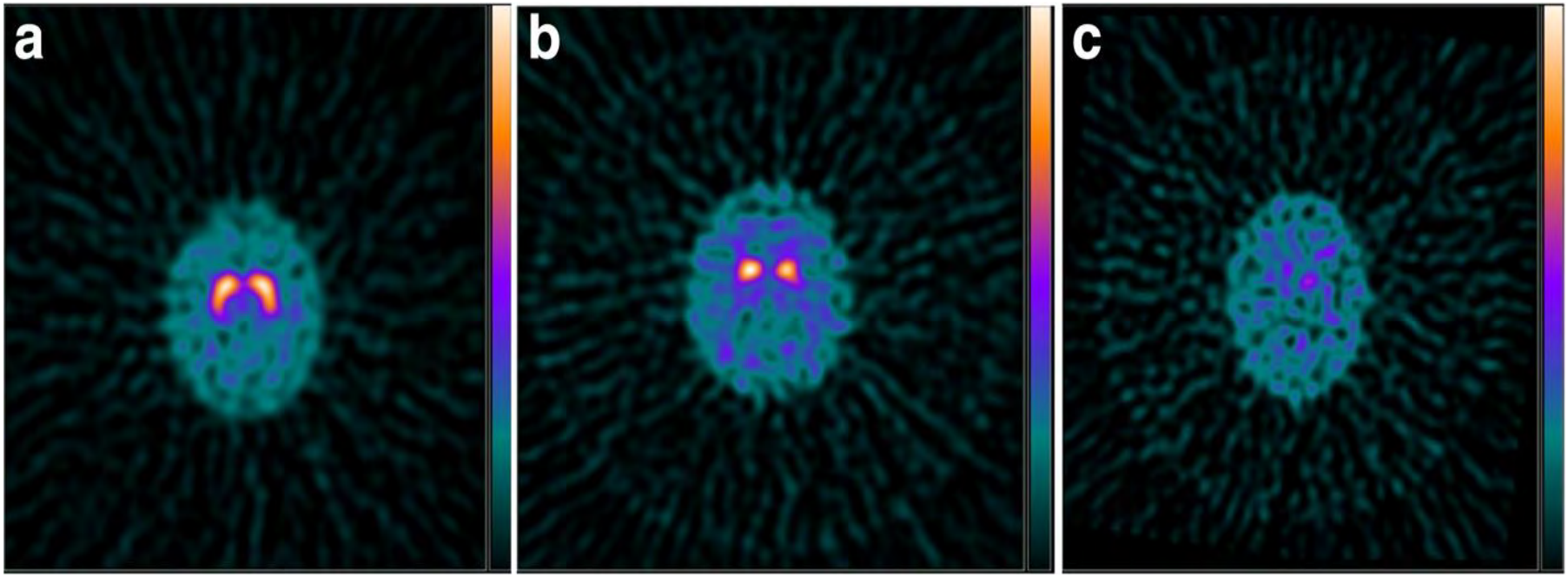

Normal DaT

+ for PD

Suggestive of DLB

Conclusion I-123 DaT Scan for ET vs PD

Diagnostic tool

- ET vs PD
- DLB vs AD

Treatment Planning

- Surgical Planning
- Optimal medication treatment

Epilepsy

Epilepsy

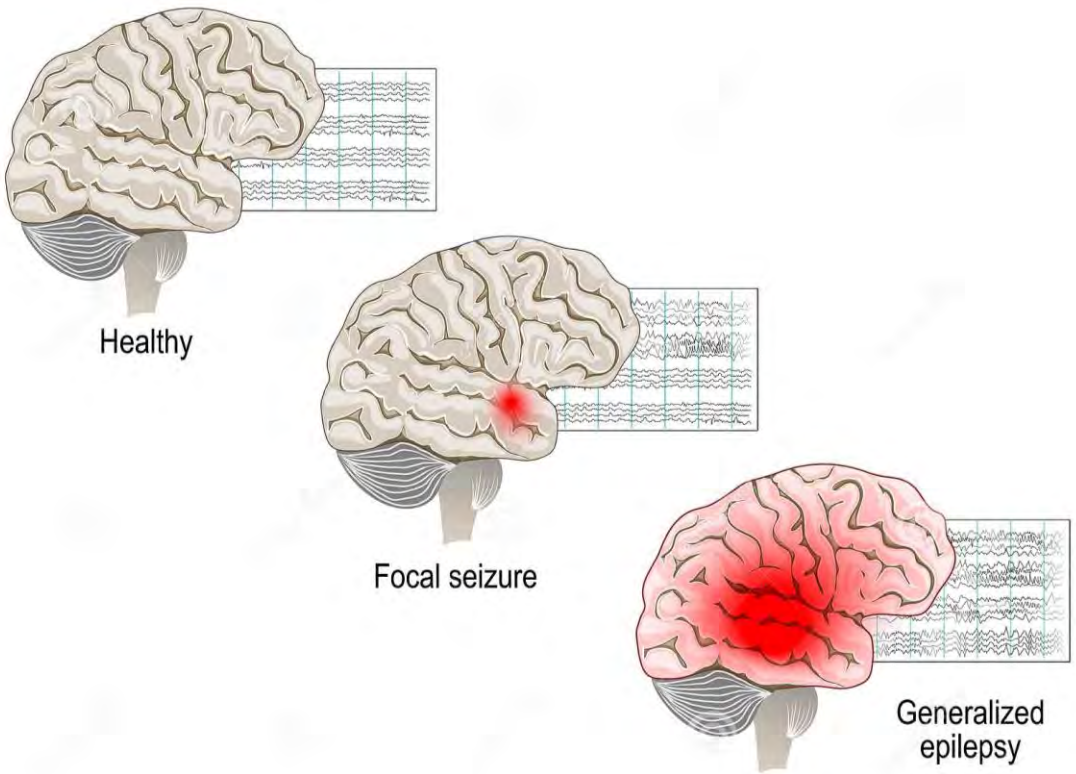

A neurological disorder marked by sudden recurrent episodes of sensory disturbance, loss of consciousness, or convulsions, associated with abnormal electrical activity in the brain.

Epilepsy with SPECT

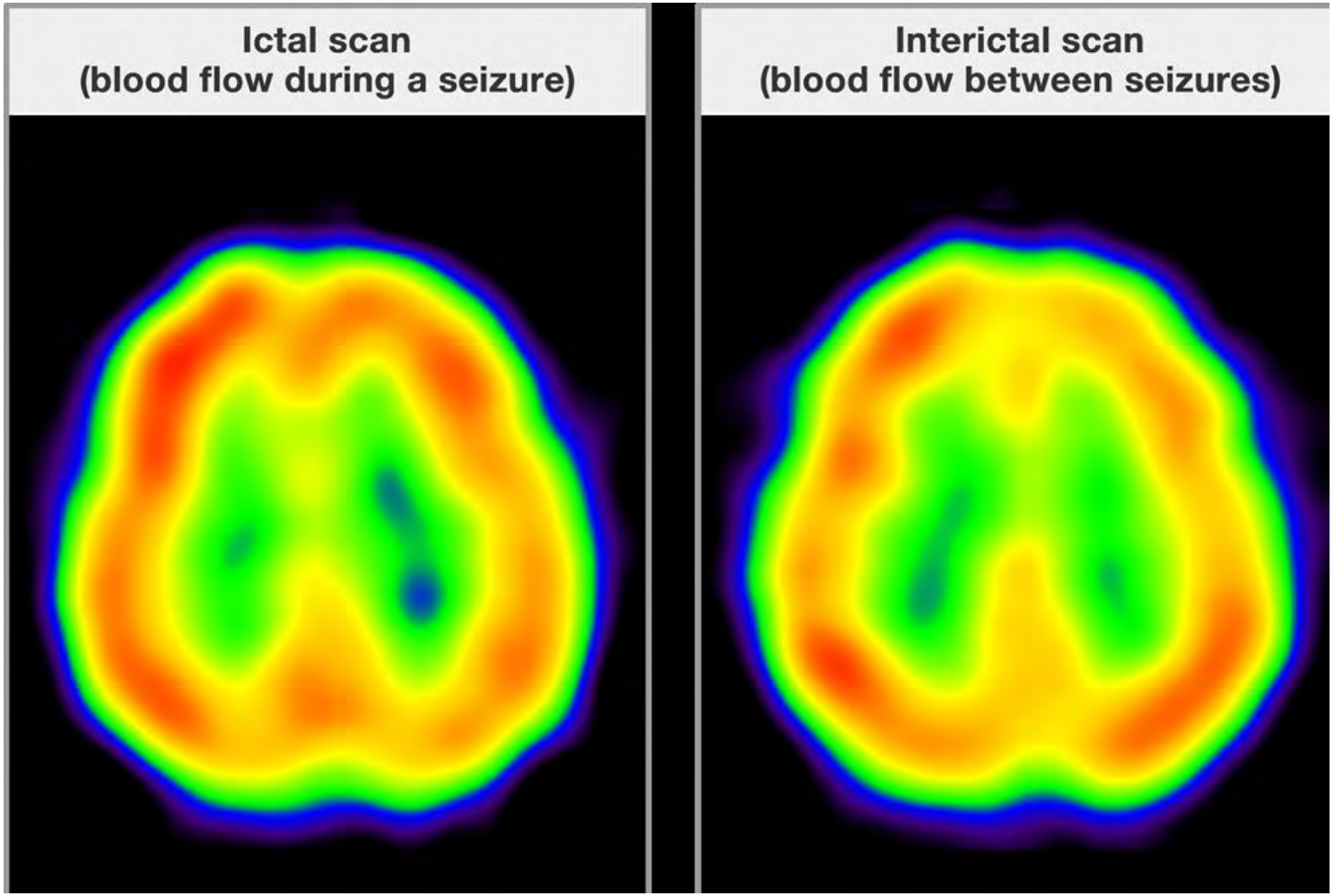

Epilepsy Imaging: SPECT Tc99m

Tc99m HMPAO (Ceretec)
Dose: 15mCi-30mCi
Delay time: 40-90 min

Tc99m EDC (Neurolite)
Dose: 30 mCi
Delay Time: 20-45 min

Prep
- Monitor Seizure Activity

Inj
- Inj Rapid bolus at first onset

Scan
- Position comfortably
- SPECT w/ fan beam collimators
- 128x128 continuous scan

Epilepsy SPECT Images

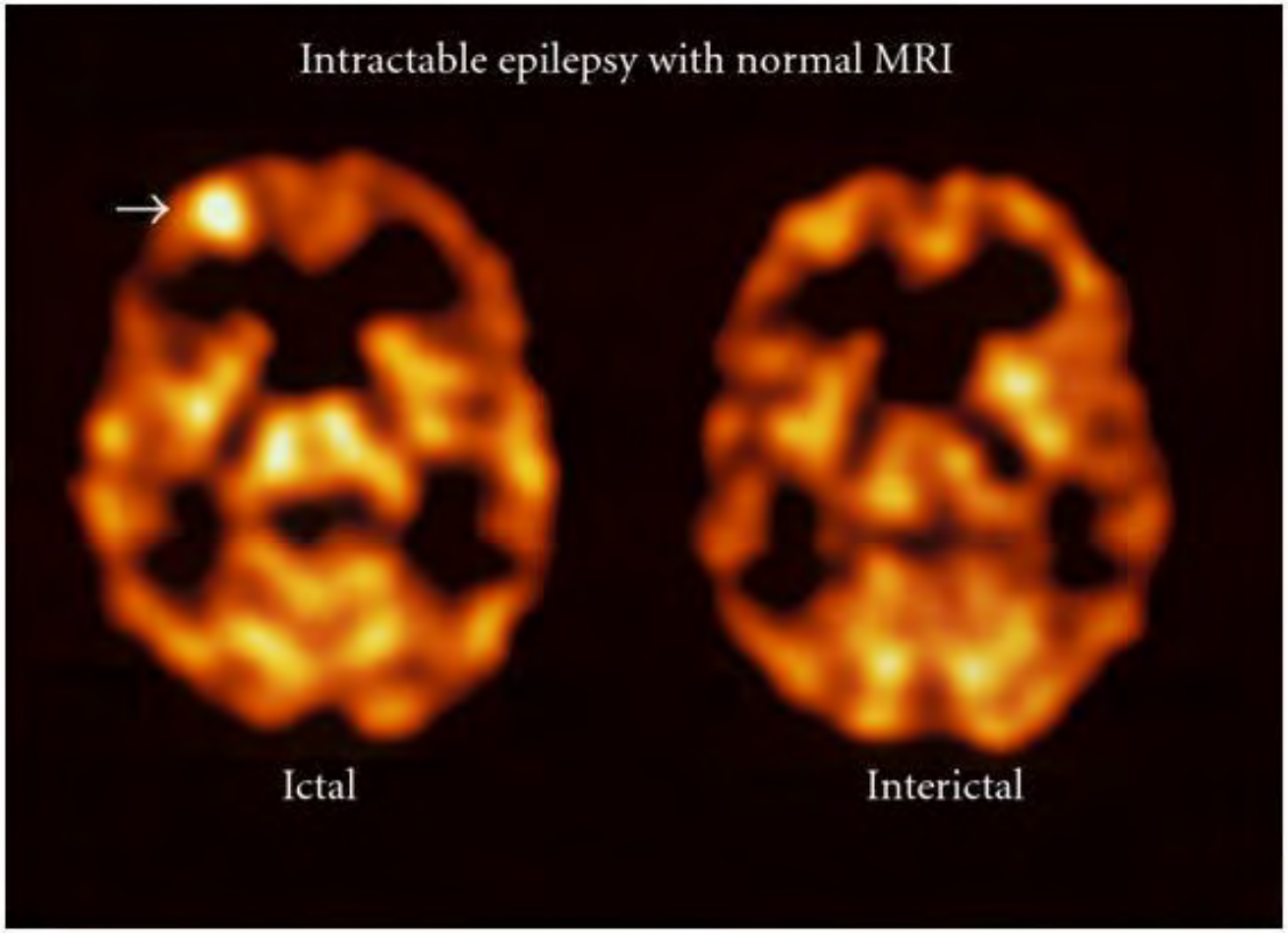

Epilepsy Imaging with PET

Subtle asymmetric decreased metabolic activity in the right medial temporal lobe suggests mesial temporal lobe sclerosis, when correlated with recent MRI.

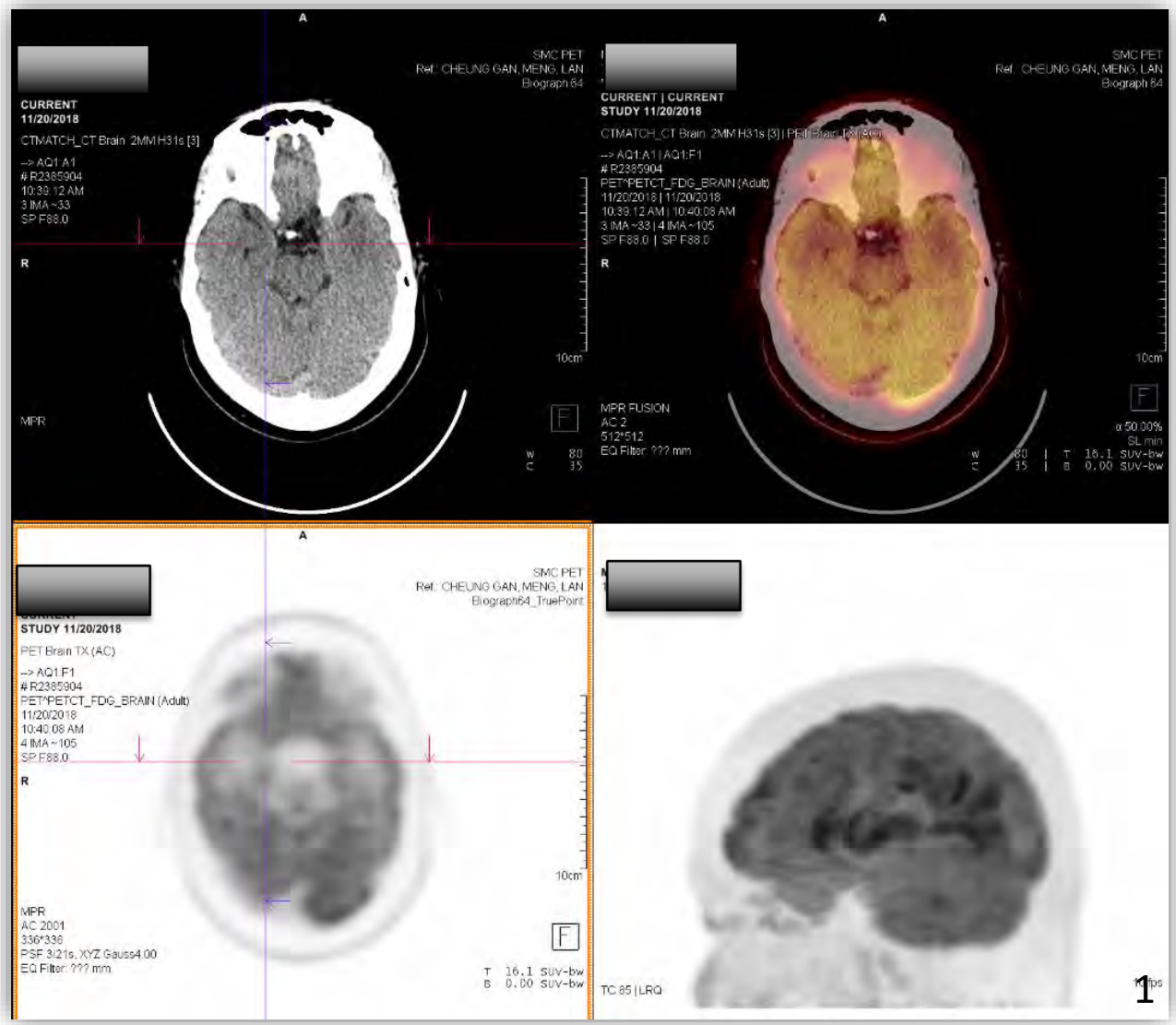

UTSouthwestern Medical Center

Epilepsy Imaging PET Protocol

F-18 fluorodeoxyglucose (FDG)

Dose: 5 mCi

Delay time 30-60 min

Prep

- NPO 4-6 hr
- Blood Glucose 150 mg/dL
- Rest ~ 30 min in dimly lit, quiet room

Injection

- 5 mCi (+/- 10%) F-18 FDG IV
- Uptake 30-60 min (dimly –lit, quiet room)

Imaging

- Position comfortably to image entire brain
- Static Image with CT attenuation

Epilepsy Imaging: F-18 FDG PET

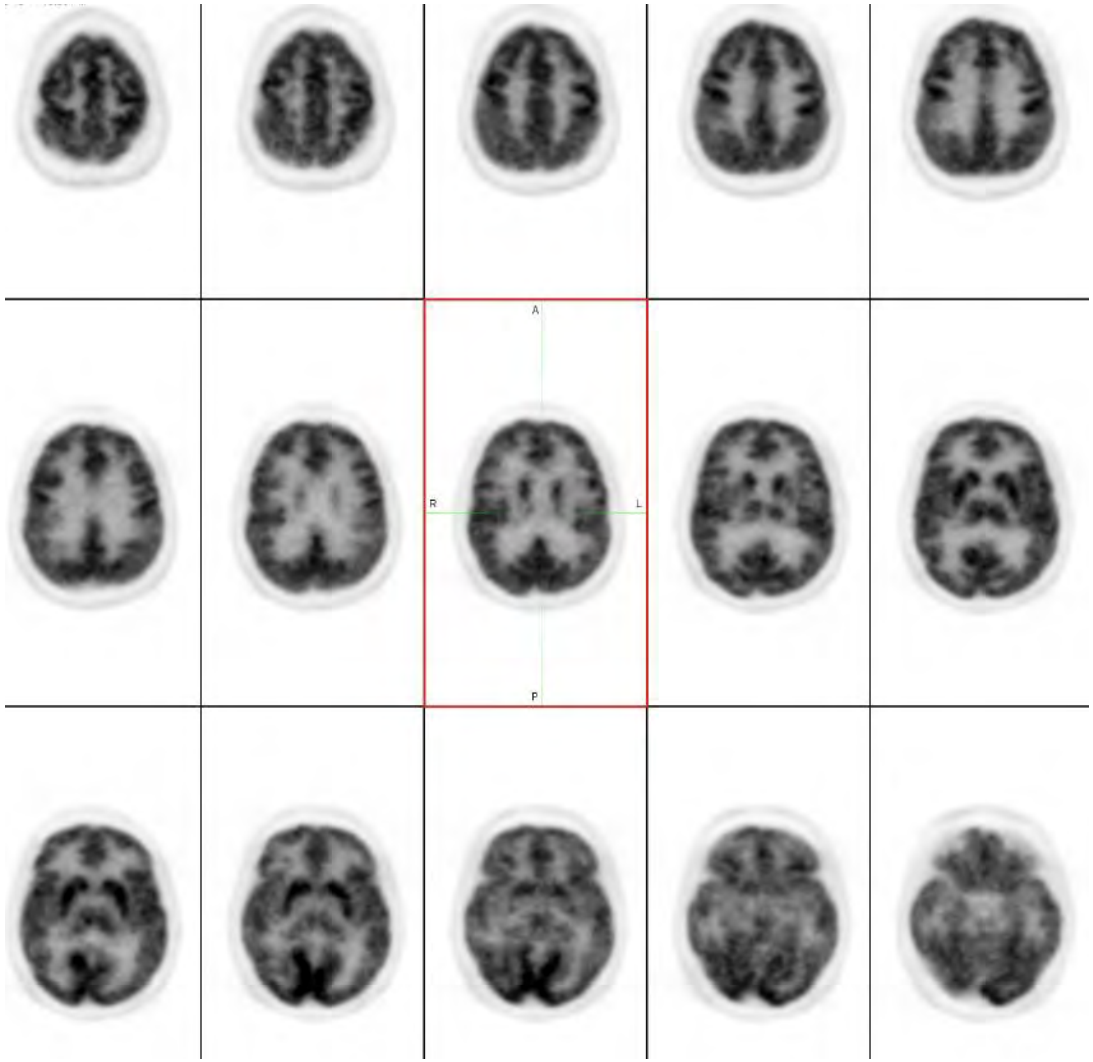

Epilepsy Imaging PET

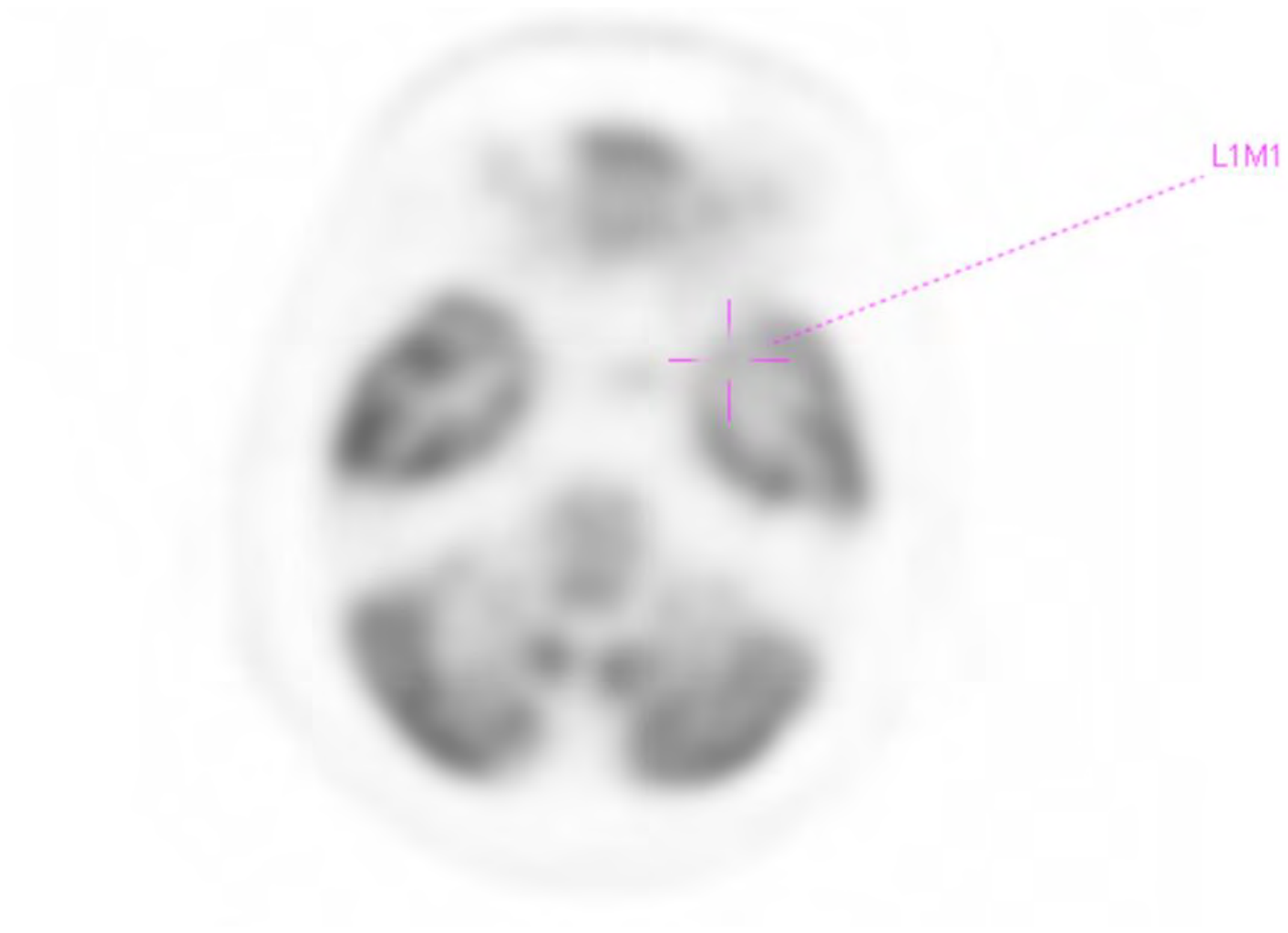

Conclusion - Epilepsy

Localization

- Provide additional information of the epileptogenic zone

Surgery Planning

- Reduce need for invasive procedures
- Select surgical candidates

Primary Dystonia & Gilles de la Tourette Syndrome

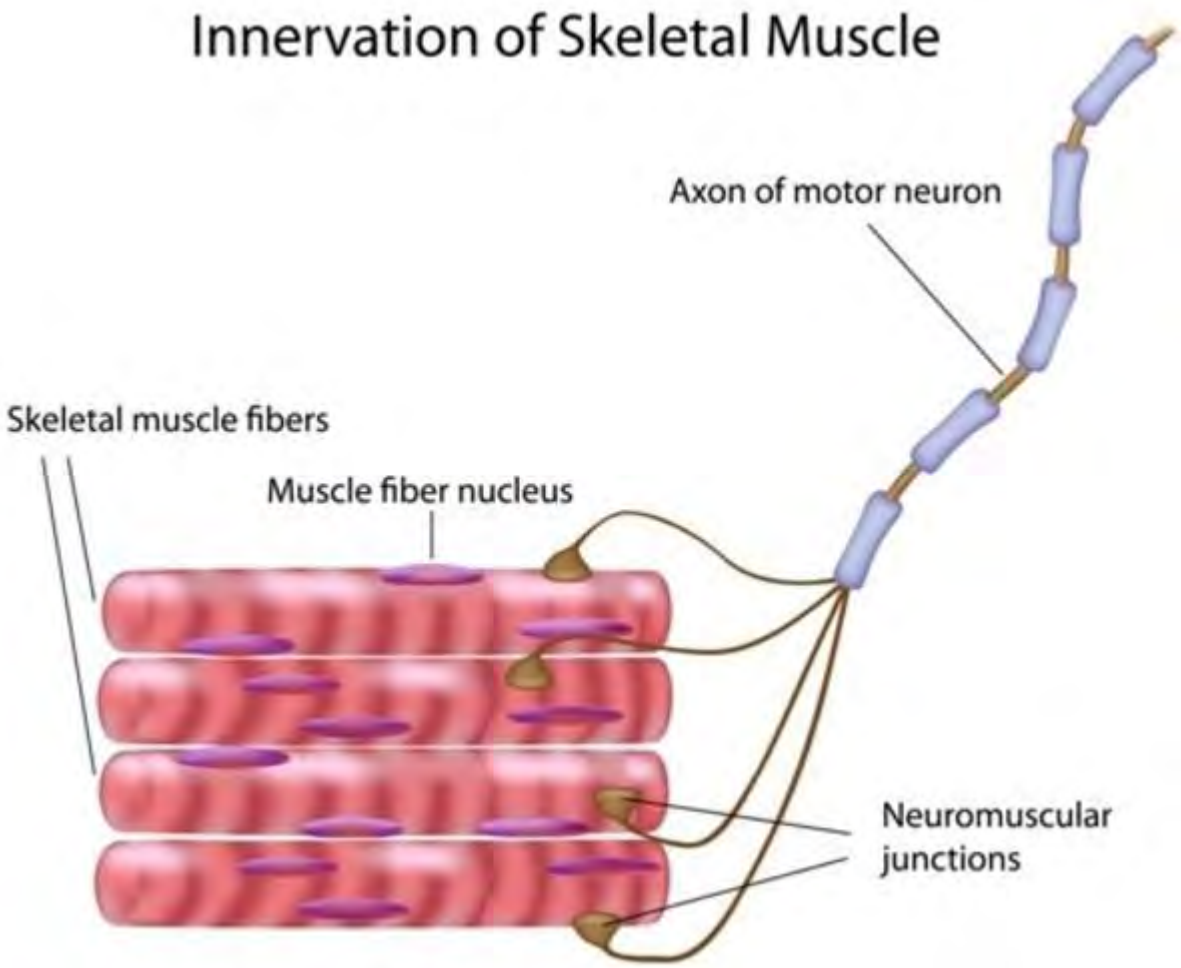
Innervation of Skeletal Muscle
Axon of motor neuron
Skeletal muscle fibers
Muscle fiber nucleus
Neuromuscular junctions

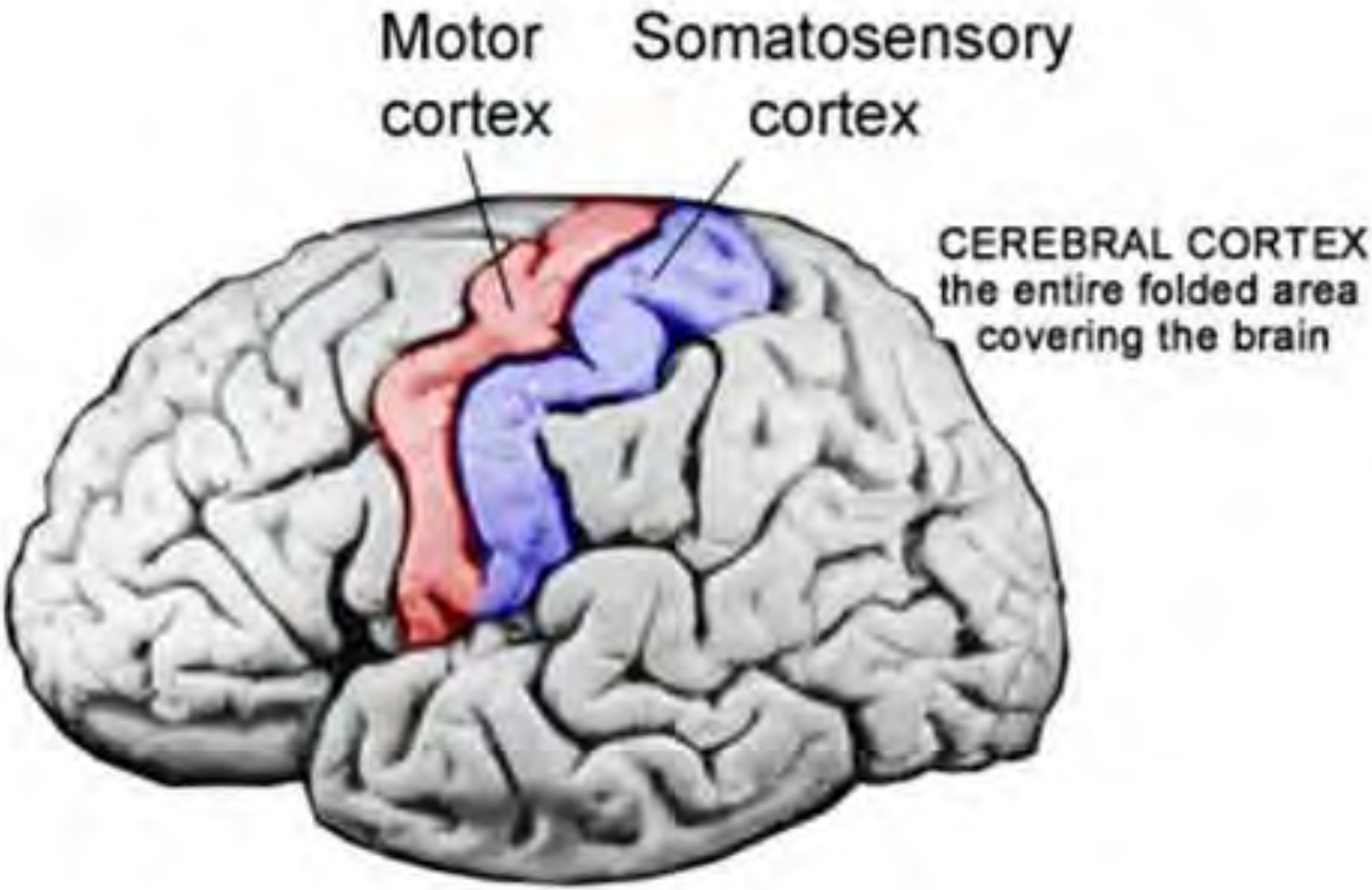
Motor cortex
Somatosensory cortex
CEREBRAL CORTEX
the entire folded area covering the brain

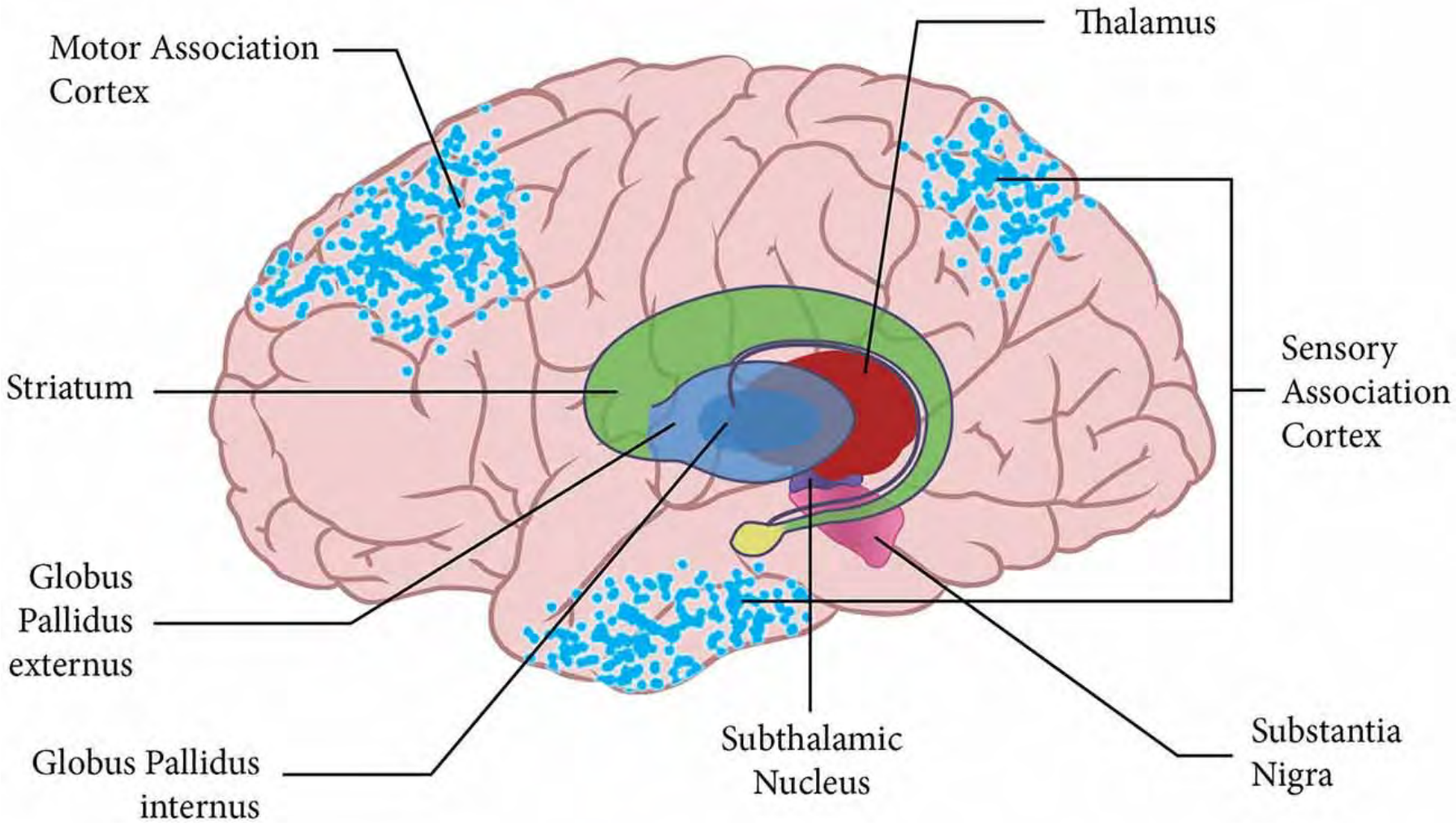
Motor Association Cortex
Thalamus
Striatum
Sensory Association Cortex
Globus Pallidus externus
Globus Pallidus internus
Subthalamic Nucleus
Substantia Nigra

pD+ Uptake

- ***Hypermetabolism*** of basal ganglia & sensorimotor pathways

GTS+ Uptake

- ***hypermetabolism*** at sensorimotor cortex level & ***hypometabolism*** in the limbic cortex and striatum

Brain PET Imaging Protocol

Prep

- NPO 4-6 hr
- Blood Glucose 150 mg/dL
- Rest ~ 30 min in dimly lit, quiet room

Injection

- 5 mCi (+/- 10%) F-18 FDG IV
- Uptake 30-60 min (dimly –lit, quiet room)

Imaging

- Position comfortably to image entire brain
- Static Image with CT attenuation

GTS PET Images

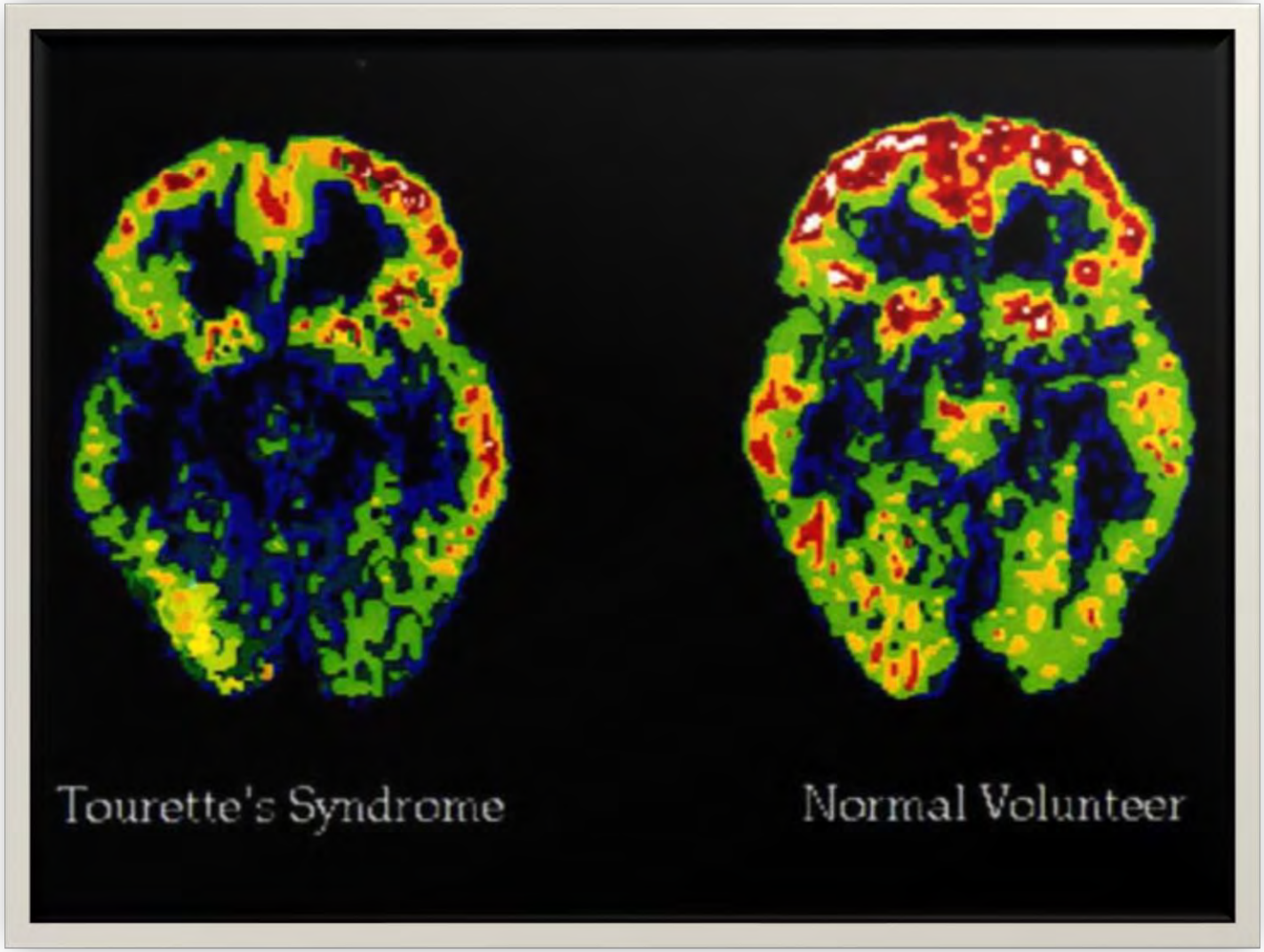

Conclusion pD & GTS

Diagnostic Tool

- Diagnosing
- Disease Monitoring

Treatment Planning

- Personalized treatment therapies
- Treatment monitoring

Future PET Applications

Huntington's Disease

Repeat expansion mutation

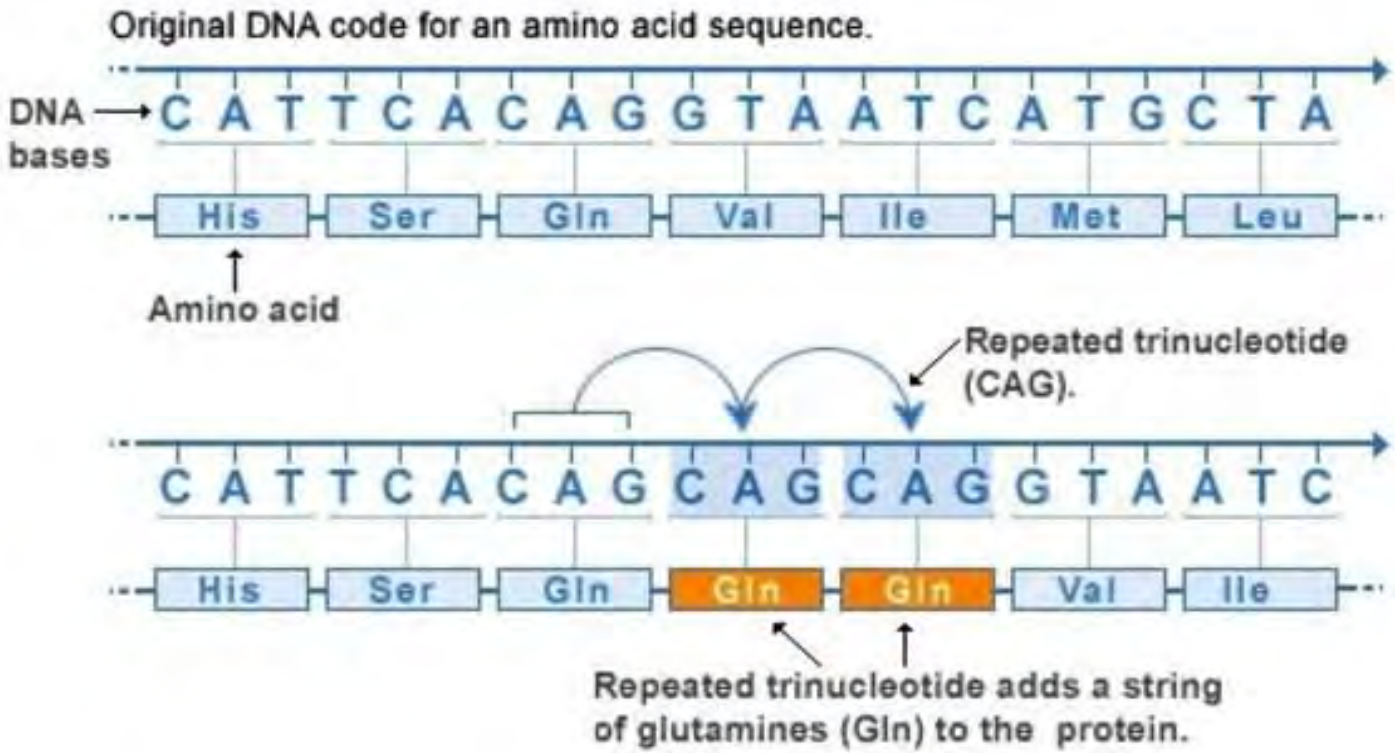

U.S. National Library of Medicine

Huntington's Disease Imaging PET

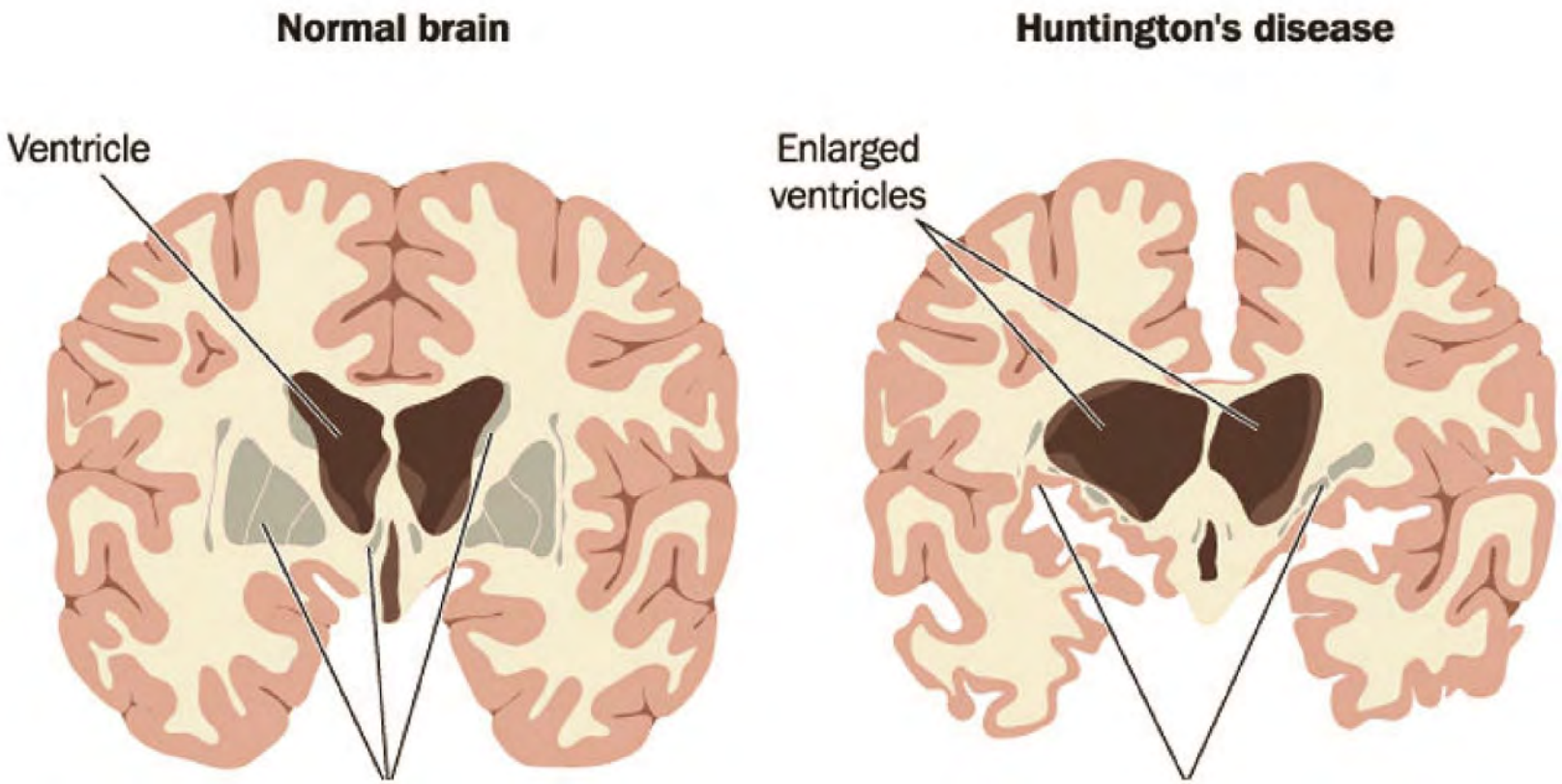

Basal Ganglia

Atrophy of tissue and Basal ganglia

Huntington's Disease Uptake

Pre-synaptic | Post-synaptic | F-18 FDG Uptake

Normal Striatum function

Decrease Striatum function

Decreased Striatum uptake & minor decrease in front-temporal cortex uptake

Brain PET Imaging Protocol

Prep

- NPO 4-6 hr
- Blood Glucose 150 mg/dL
- Rest ~ 30 min in dimly lit, quiet room

Injection

- 5 mCi (+/- 10%) F-18 FDG IV
- Uptake 30-60 min (dimly –lit, quiet room)

Imaging

- Position comfortably to image entire brain
- Static Image with CT attenuation

Huntington's Disease Images

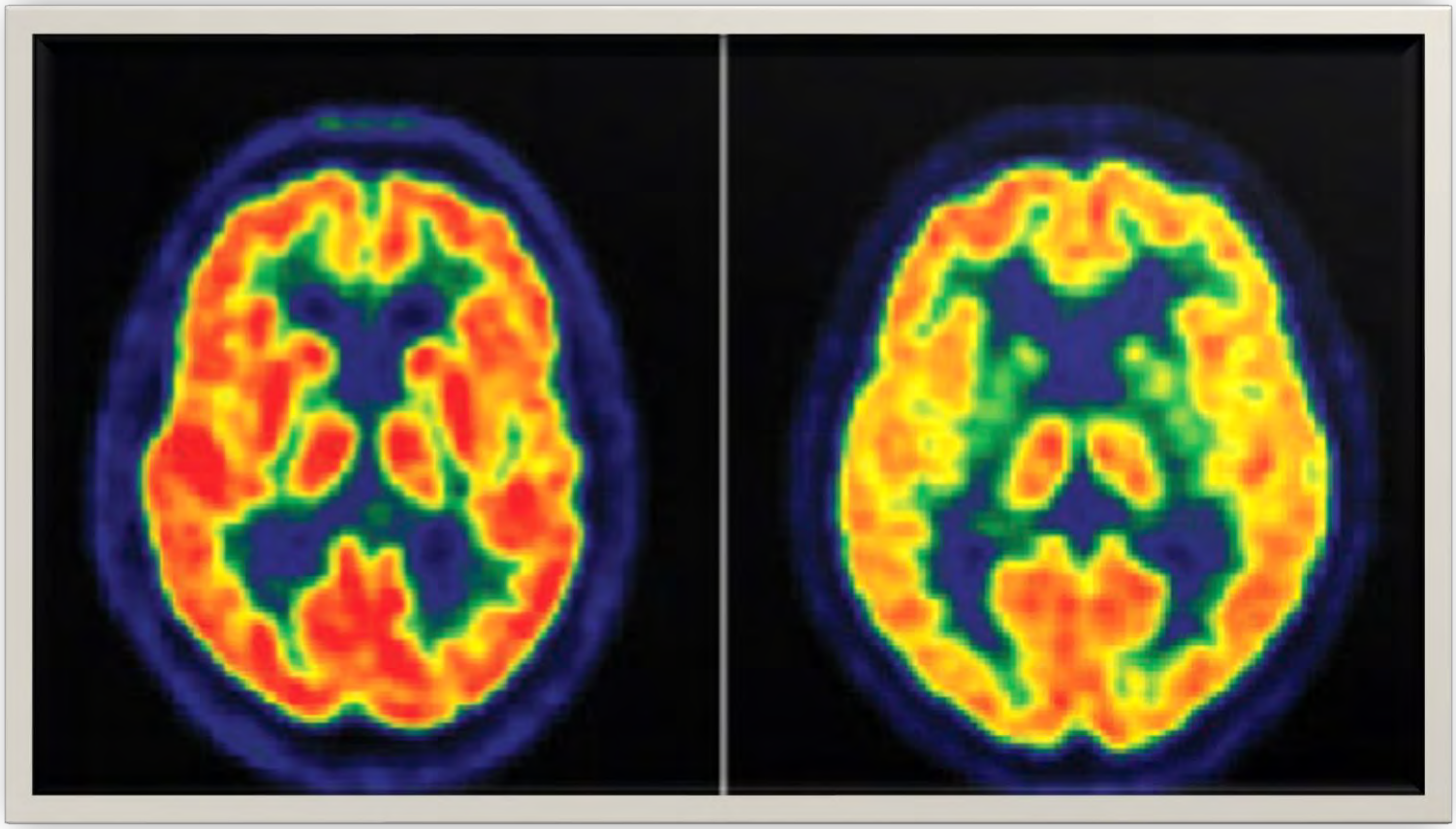

Control HD

Huntington's Disease Images

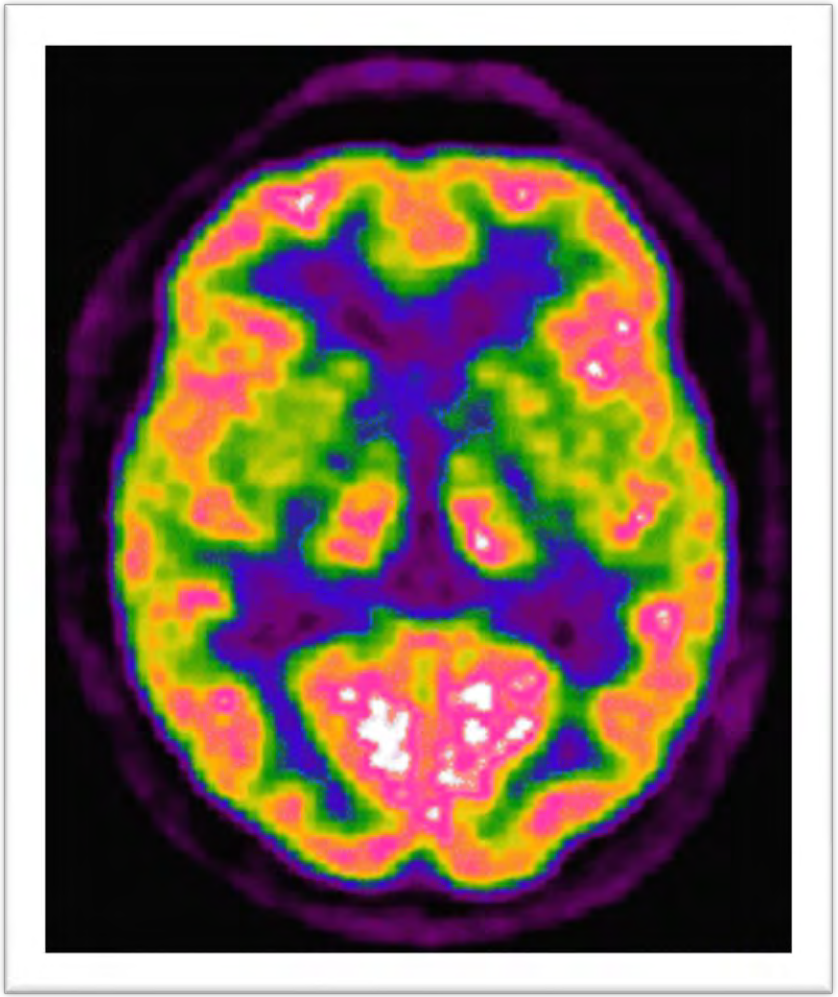

Conclusion HD

Promising Outlook

- Diagnostic tool
- Disease Monitoring

Future Research

- Enzyme expression imaging
- Activated Macrophage role

Amyotrophic Lateral Sclerosis

Amyotrophic Lateral Sclerosis

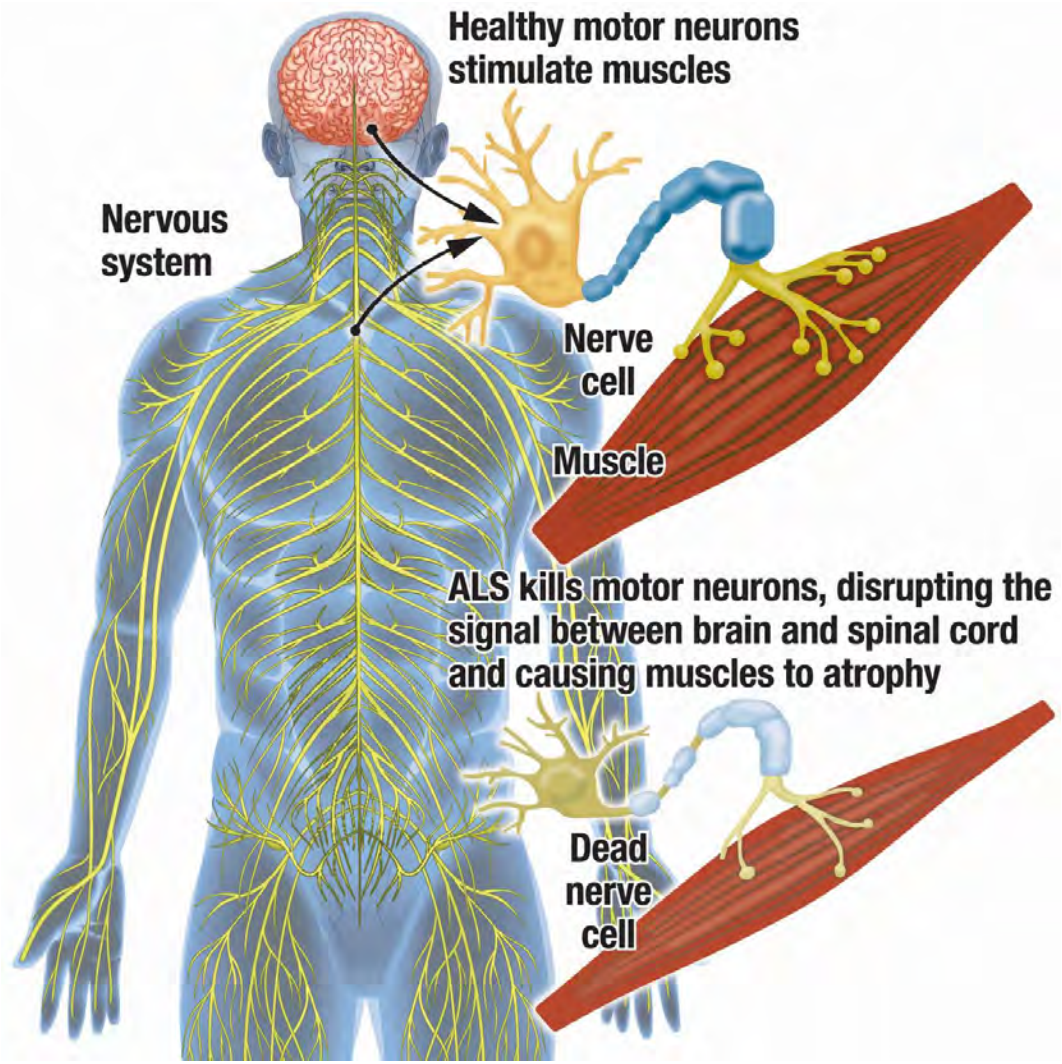

ALS with F-18 FDG Uptake Pattern

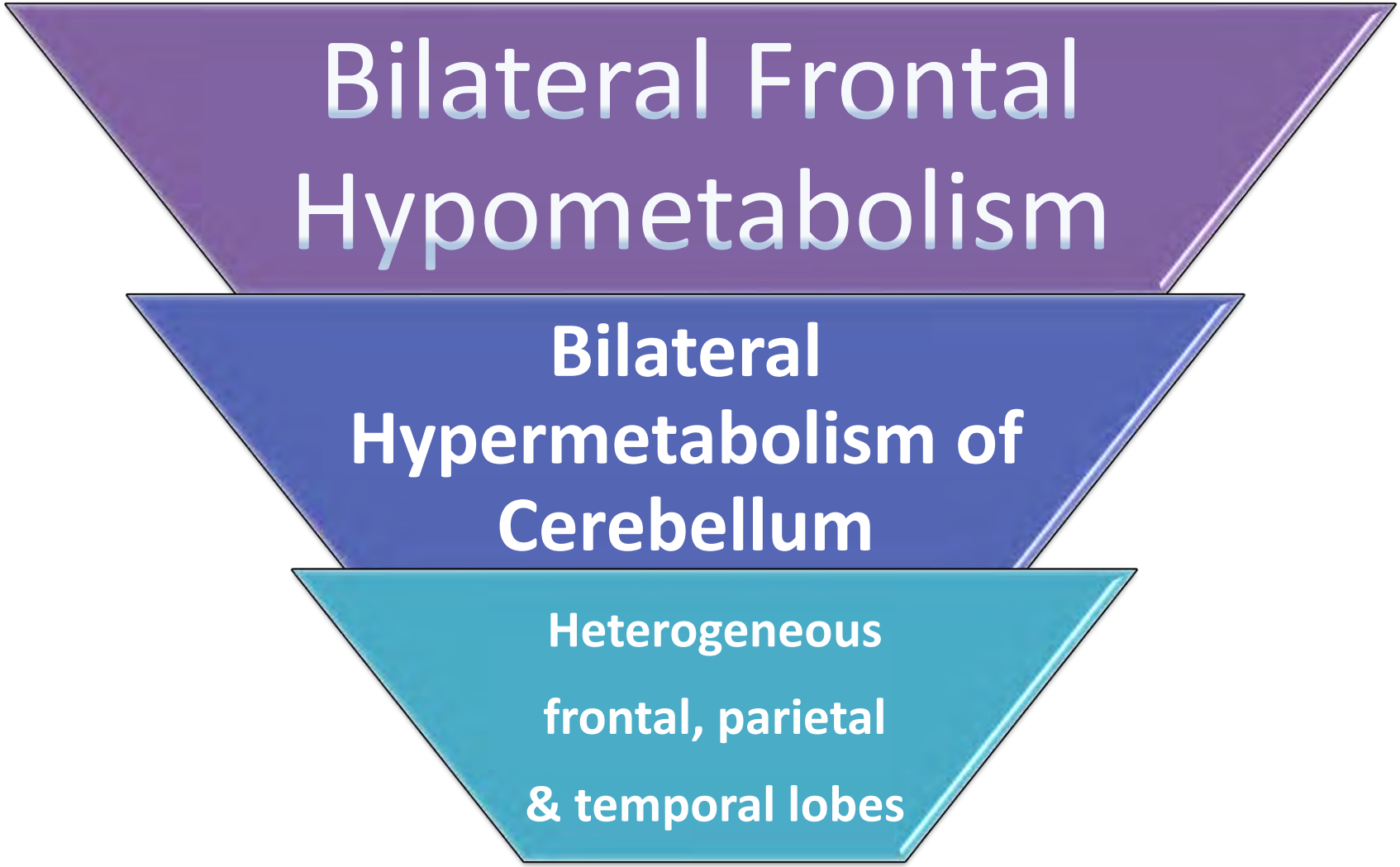

Brain PET Imaging Protocol

Prep

- NPO 4-6 hr
- Blood Glucose 150 mg/dL

Injection

- 5 mCi (+/- 10%) F-18 FDG IV
- Uptake 30 min (dimly –lit, quiet room, eyes closed)

Imaging

- Position comfortably to image entire brain
- Static Image with CT attenuation
- 15 min single bed, static image

ALS PET Images

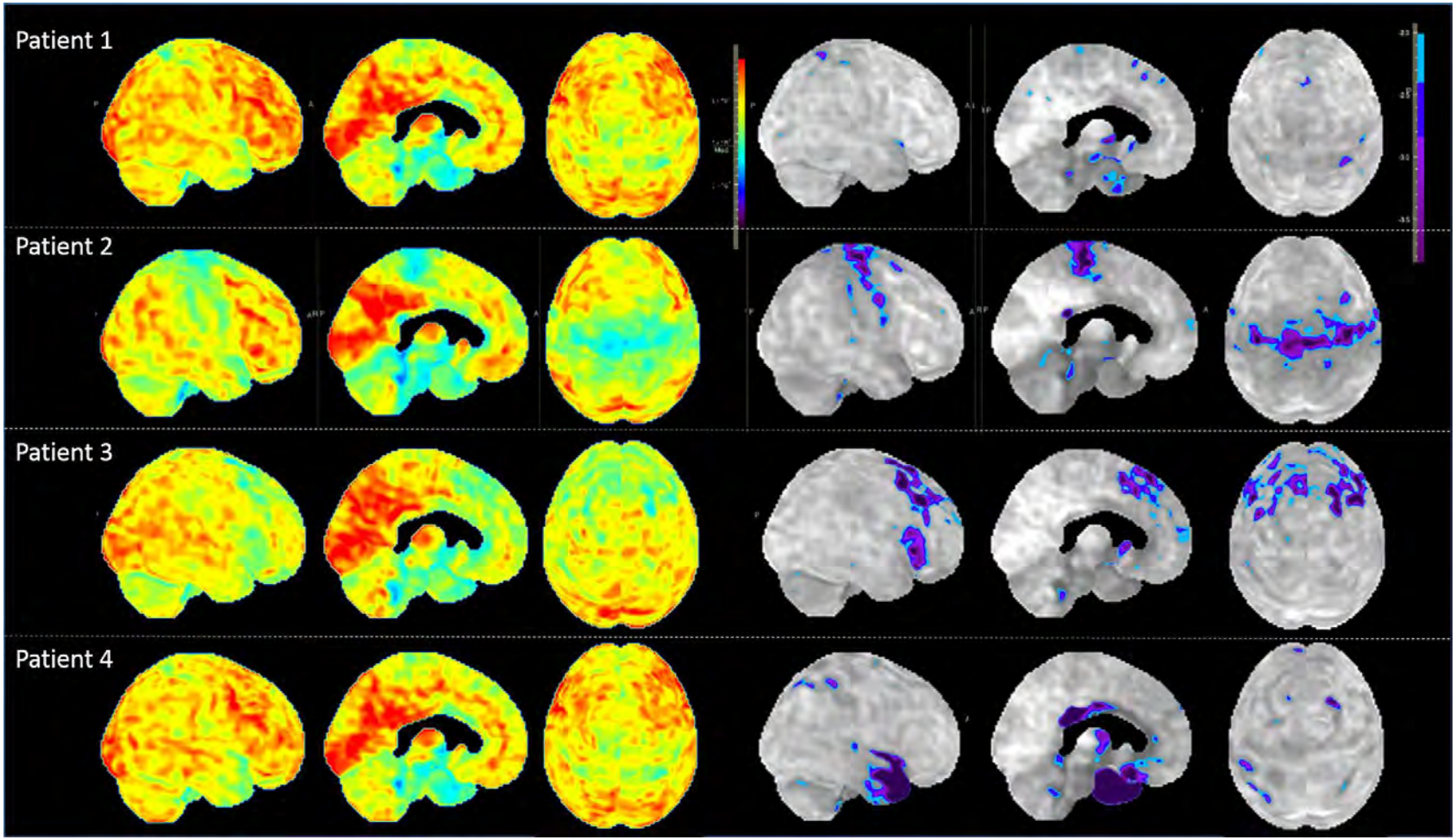

ALS PET Images

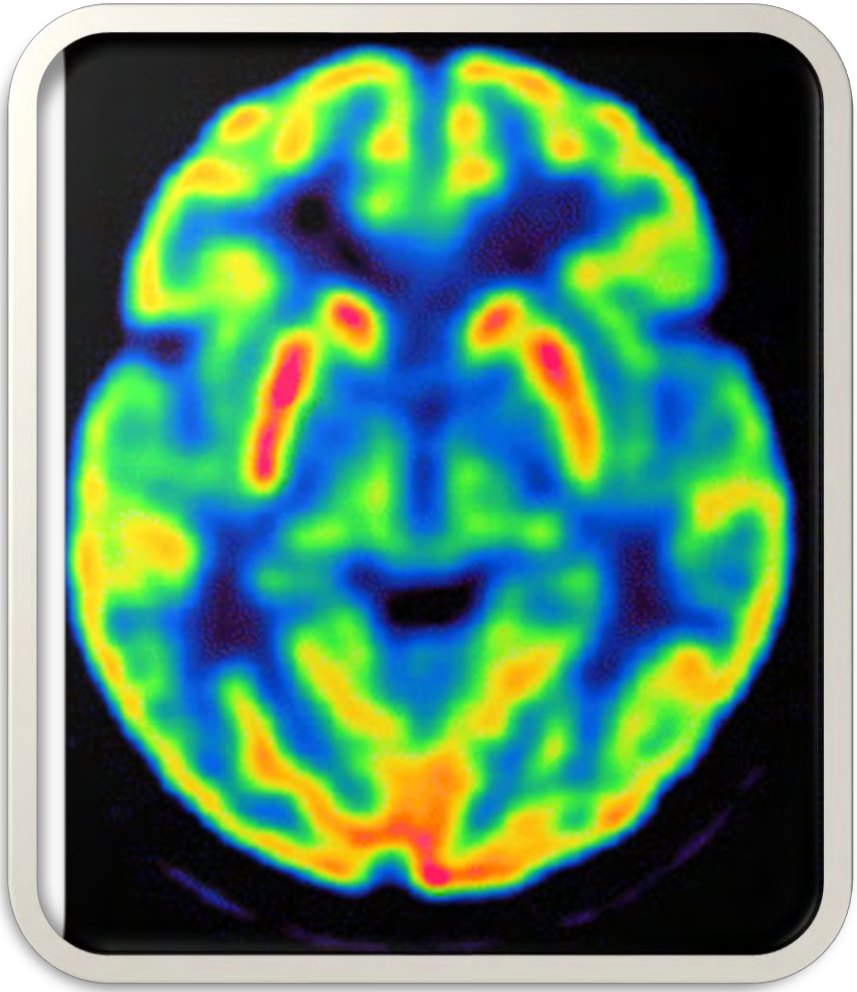

Conclusion ALS

Promising Outlook

- Diagnostic tool
- Disease Monitoring
  - F18 Amyloid imaging

Research Pit-Falls

- Small number and poor clinical characterization of patients
- Absence of adequate controls
- Scarcity of longitudinal assessments

Conclusion

PD v ET

- I 123 DaT Imaging

Epilepsy

- Tc99m Ictal & Interictal SPECT
- F-18 FDG PET/CT

pD & GTS

- F18 FDG PET/CT

Conclusion

HD

- F-18 FDG PET/CT

ALS

- F-18 FDG PET/CT
- F-18 Amyloid PET/CT

Thank you!

References

- Society of Nuclear Medicine and Molecular Imaging. (2016). Molecular Imaging and the Brain. Reston, VA 20190 www.snmmi.org
- Karlo L, Alessandra G, Wei C, Antonio A. (March 28, 2016) Molecular imaging of movement disorders. World Journal of Radiology. Volume 8 (Issue 3).www.wjgnet.com
- Kirk F. (2017). Molecular Imaging of Extrapyramidal Movement Disorders. Elsevier. http://dx.doi.org/10.1053/j.semnuclmed.2016.09.007
- Nichols et al. European Journal of Hybrid Imaging (2018) 2:10 https://doi.org/10.1186/s41824-018-0028-0
- Andreas-AntoniosR, Paola P. (2015) PET Imaging in Huntington's Disease. Journal of Huntington's Disease, 4
- Maliha S, John S, Anna C, Ram B, and Ana M. (2014) Molecular Imaging Insights into Neurodegeneration: Focus on a-Synuclein Radiotracers. Focus on Molecular Imaging. Journal of Nuclear Medicine. Volume 55 (9). jnm.snmjournals.org

References

- Asenbaum, S, Baumgartner, C. (Jan 25, 2001). Nuclear medicine in the preoperative evaluation of Epilepsy. Nuclear Medicine Communications, 22, 835-840.
- Boscutti G, A Rabiner E, Plisson C, PET Radioligands for imaging of the PDE10A in human: current status, Neuroscience Letters (2018). https://doi.org/10.1016/j.neulet.2018.08.006
- Atul M, Alexander D, Satoshi M. (2017) Precision Medicine in Dementia and Movement Disorders. PET Clin 12, 119-136.
- Pierpaolo, A, Leonardo I, and Daniela P. (September 23, 2014). PET neuroimaging: insights on dystonia and Tourette syndrome and potential applications. Frontiers in Neurology, Volume 5 (issue 183).
- Moretti et al. (May 21, 2008). What every psychiatrist should know about PANDAS. Clinical Practice and Epidemiology in Mental Health, Volume 4, (Issue 13).

References

- Jordi A. et al. (Jan 25, 2016). Amyloid- and FDG-PET imaging in amyotrophic lateral sclerosis. Eur J Nucl Med Mol Imaging, Volume 43 (Issue 20).
- Abass A, (May 9, 2011). SPECT Imaging of Epilepsy: An Overview and Comparison with F-18 FDG PET. Hindawi Publishing Corporation. Volume 2011, Article ID 813028, 9 pages.
- David, D et al. (Nov 11, 2011). SNM Practice Guideline for Dopamine Transporter Imaging with 123I-Ioflupane SPECT 1.0. THE JOURNAL OF NUCLEAR MEDICINE, Vol. 53 (Issue 1).
- Swinnwn, B. et al. (Sept. 14, 2016). PET Imaging in ALS, Update on Amyotrophic Lateral Sclerosis, Humberto Foyaca Sibat and Lourdes de Fatima Ibanez Valdes, IntechOpen. www.intechopen.com/books/update-on-amyotrophic-lateral-sclerosis/pet-imaging-in-als

Special Images

- http://www.brainfacts.org/thinking-sensing-and-behaving/movement/2015/dopamine-and-movement
- https://www.mayfieldclinic.com/PE-PD.htm
http://www.alsa.org/about-als/what-is-als.html
- https://www.download.thelancet.com/journals/laneur/article/PIIS1474-4422(14)70167-X/fulltext